



# Comparison of Titanium Elastic Nailing and End-threaded Intramedullary Pinning for Distal Femoral Fractures in Young Dogs

Harmanpreet Singh Sodhi<sup>1</sup>, Ashwani Kumar<sup>1</sup>,  
Arun Anand<sup>1</sup>, Vandana Sangwan<sup>1</sup>, Opinder Singh<sup>2</sup>

10.18805/IJAR.B-4454

## ABSTRACT

**Background:** Femur fractures are common in immature dogs. As compared to stainless steel, titanium implants are lighter and allow controlled micro-motion at the site of fracture that stimulates early callus formation by limiting stress shielding. Cited literature reports successful clinical use of titanium elastic nails for the stabilization of long bone fractures in young human patients; however, there is paucity of information on this technique in dogs. This study was planned with an objective to compare titanium elastic nails (TENS) and single end-threaded pin for the management of femoral fractures in young dogs.

**Methods:** The study included 20 clinical cases (10 male and 10 female) of dogs suffering from distal femoral fracture with a mean±SD age of 5.70±5.60 month, body weight 11.09±4.48 kg since 3.05±2.35 days. The cases were divided into 2 groups; using TENS (n=10; group 1) and stainless steel end-threaded intramedullary pin (n=10; group 2).

**Result:** Group 1 dogs demonstrated better fracture reduction score, early and uniform callus and better implant stability as compared to group 2, radiographically. Early weight bearing and minimum postoperative complications with better functional outcome including joint mobility was reported in group 1. In conclusions, TENS is superior fracture fixation technique for the repair of supracondylar or distal third femur fractures in young dogs with better functional outcome, minimal stiffness of stifle joint and early weight bearing, in comparison to single end threaded intramedullary pin.

**Key words:** Canine, End threaded pin, Femur fracture, Orthopedic surgery, Titanium elastic nails.

## INTRODUCTION

Femur is the most commonly affected bone with high occurrence of supracondylar and distal metaphyseal fractures in young growing dogs (Aithal *et al.*, 1999). The fixation of distal diaphyseal fractures poses several challenges during perioperative period (Kaur *et al.*, 2016) with intramedullary fixation techniques considered more biological (Kumar *et al.*, 2020). Several techniques such as cross pinning (Gill *et al.*, 2018), dynamic cross pinning (Whitney and Schrader, 1987), stack pinning (Altunatmaz *et al.*, 2017), simple (Shires and Hulse, 1980) and end-threaded IM pinning (Kaur *et al.*, 2015; Kaur *et al.*, 2016; Gill *et al.*, 2018) have been described to stabilize distal third, metaphyseal or supracondylar femoral fractures in dogs. The threaded portion of the pin may damage the growth plate to an extent to hamper the bone growth; but there is lack of studies on this aspect.

Titanium implants are lighter in weight and allow controlled micromotion at the site of fracture that stimulates early callus formation by limiting stress shielding. Titanium has lower modulus of elasticity as compared to stainless steel making it ideal for use in young human patients (Mahar *et al.*, 2004; Bhaskar, 2005). There is paucity of literature on TENS clinical application in dogs. The present study was planned with an objective to compare titanium elastic nails and single end-threaded pin for the repair of femoral fractures in young dogs.

<sup>1</sup>Department of Veterinary Surgery and Radiology, College of Veterinary Science, Guru Angad Dev Veterinary and Animal Sciences University, Ludhiana-141 004, Punjab, India.

<sup>2</sup>Department of Veterinary Anatomy, College of Veterinary Science, Guru Angad Dev Veterinary and Animal Sciences University, Ludhiana-141 004, Punjab, India.

**Corresponding Author:** Harmanpreet Singh Sodhi, Department of Veterinary Surgery and Radiology, College of Veterinary Science, Guru Angad Dev Veterinary and Animal Sciences University, Ludhiana-141 004, Punjab, India.  
Email: harmansodhi11@yahoo.com

**How to cite this article:** Sodhi, H.S., Kumar, A., Anand, A., Sangwan, V. and Singh, O. (2023). Comparison of Titanium Elastic Nailing and End-threaded Intramedullary Pinning for Distal Femoral Fractures in Young Dogs. Indian Journal of Animal Research. 57(9): 1186-1193. doi: 10.18805/IJAR.B-4454.

**Submitted:** 18-03-2021 **Accepted:** 25-08-2021 **Online:** 24-09-2021

## MATERIALS AND METHODS

The clinical study was duly approved by the CPCSEA. It included 20 clinical cases of dogs (10 male and 10 female) suffering from distal femoral fracture with a mean±SD age of 5.70±5.60 month (range 1.00-27.00 month), body weight 11.09±4.48 kg (range 2-22 kg) since 3.05±2.35 days (range 1-8 days) associated with automobile accident (n=9),

fall from lap (n=7) or from height (n=4). Various breeds such as German Shepherd and Labrador (4 each), Pomeranian and crossbred (3 each), Beagle (2) and Golden Retriever, Pit bull and Rottweiler (1 each) affected with right (n=14) or left (n=6) femur. Dogs with other associated orthopaedic, pelvic or spinal injuries were excluded. The fractures were stabilized using titanium elastic nails (n=10; group 1) and stainless steel end-threaded intramedullary pins (n=10; group 2).

The femur including stifle and hip joints radiographed in lateral and antero-posterior views preoperatively. Immediate postoperative radiographs were graded for reduction (grade 0 to 3) as described by Cook *et al.* (1999). Subsequently, the radiographs obtained at 12<sup>th</sup> and 45<sup>th</sup> day were assessed for implant stability and progression of fracture healing. Radiographic scoring of fracture healing (0-3) based on callus formation and/or elimination of the fracture line or gap (Cook *et al.*, 1999) was done.

All fractures were repaired under general anesthesia using inj. butorphenol @ 0.2 mg/kg, inj. acepromazine @ 0.05 mg/kg and inj. atropine @ 0.04 mg/kg as premedication. Anesthesia was induced with inj. propofol, IV @ 4 mg/kg or 'till effect' and was maintained on isoflurane.

In group 1 (TENS), apart from standard surgical pack, titanium nails (1.0 to 2.5 mm) (Fig 1) with pre-bent tips,

curved pointed awl (Fig 2a), bone chuck with extension rod and hammer (Fig 2b, c and d), Plier (Fig 2e) and wire/pin cutter (Fig 2f) were also used.

For open reduction of supracondylar/distal fractures of femur, the cranio-lateral surgical approach described by Johnson (2014) was followed. A pilot hole using awl was made each at the medial and lateral sides of femoral condyles (Fig 3a). Two titanium nails of same size (<40% of medullary canal diameter) were inserted from the distal end upto the fracture site using bone chuck (Fig 3b) with extension rod and hammer (Fig 3c). Thereafter, the fracture was reduced and the nails were further driven proximally till the end of the bone. No pre-contouring of the titanium nails was done as described in medical literature (Mahar *et al.*, 2004). The nails protruding from the distal end of bone were bent (laterally and medially) using plier (Fig 3d) and cut as short as possible (Fig 3e) using wire/pin cutter.

In group 2, the femoral fractures were repaired by single end-threaded (stainless steel) IM pin in a retrograde fashion as described previously (Kaur *et al.*, 2016; Gill *et al.*, 2018). Care was exercised to fix fractures in a slight over correction manner and to avoid exit of the pin from the cranial (trochlear) side. Pin interference in the distal joint was checked by moving the stifle joint. The extra pin was cut close to the trochanter.

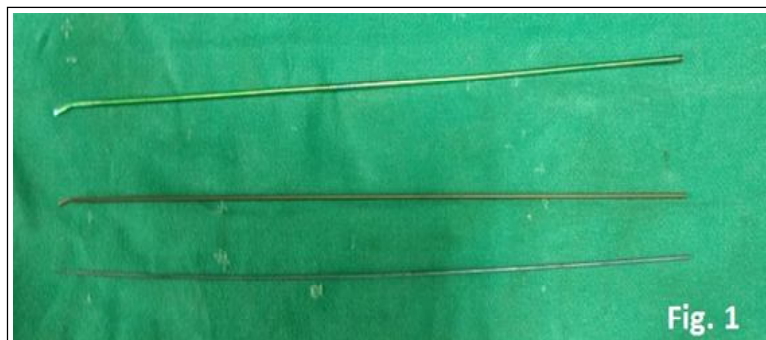



Fig 1: Titanium elastic nails of various sizes.



(a), Chuck and extension rod (b and c), Hammer for extension rod (d), Plier for pin bending (e), Pin/wire cutter (f).

Fig 2: Photograph showing curved pointed awl.

Surgical site was thoroughly flushed with sterile normal saline solution. Incised vastus lateralis muscle was sutured (Fig 4a). Joint capsule (Fig 4b) and tensor fascia lata over the joint were closed using interrupted sutures with 2-0 polyglactin 910. The fascia lata over patella was sutured in a simple continuous pattern (Fig 4c). The subcuticular tissue and skin was sutured in a routine manner (Fig 4d). Ease of fracture reduction, type/size of implant, technique used, intraoperative complications and total operative time (minutes) from skin incision to skin suturing were recorded.

The surgical wounds were dressed using 5% solution of Povidine iodine and Neosporin powder at 4 days intervals along with modified RJB for 2 to 3 weeks (Gill *et al.*, 2018). Postoperatively, all dogs were administered; inj. cefotaxime @ 20 mg/kg i.m. bid for 5 days and inj. meloxicam @ 0.2 mg/kg od i.m. for 3 days. Skin sutures were removed after 10-12 days. Calcium and Vitamin D3 supplements were advised for one month. Cage rest with leash walking was advised in the first 15 postoperative days, followed by passive exercise.

Postoperatively, functional status of the stifle joint was assessed by measuring range of motion (ROM) (subtracting maximum flexion from maximum extension) of the affected joint and contralateral joint by goniometer on 12<sup>th</sup> and 45<sup>th</sup> day of surgery as described previously (Gill *et al.*, 2018).

The operated dogs were assessed for weight bearing and functional limb usage at various intervals during the postoperative period. Total score (0-6) was evaluated by adding the scores obtained for weight bearing at standing (0-2) and walking/running (0-4) (Cook *et al.*, 1999). Clinical lameness score (0-5; 0 means no observable lameness to 5 as non-weight bearing lameness) was assigned at the final follow up examination (Cook *et al.*, 1999). Overall functional outcome was classified as full, acceptable and unacceptable function as defined by Cook *et al.* (2010).

After radiographic union of fracture, implants in group 2 were removed under local anesthesia and sedation (from proximal end of the pin with a plier rotating in anti-clockwise fashion) whereas group 1 were removed, aseptically, under general anesthesia from the distal end.

Objective data was processed for mean±SD using Microsoft Excel 2007. Comparative analysis between the groups was done using student's t-test.

### RESULTS AND DISCUSSION

The mean body weight of dogs in group 1 was significantly ( $p < 0.05$ ) higher ( $12.60 \pm 4.25$  kg) than in group 2 ( $9.18 \pm 4.34$  kg). However, the age was non-significantly different. The average duration of femur fractures in group 1 was

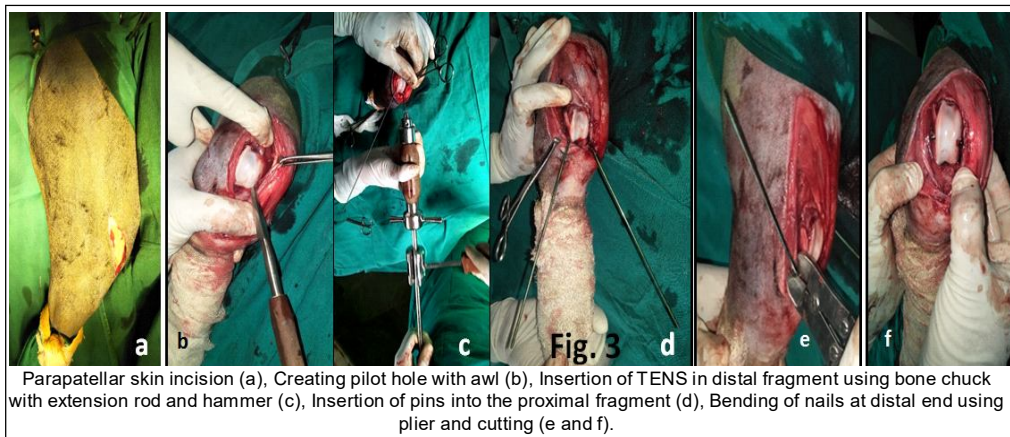


Fig 3: Serial photographs of TENS procedure.

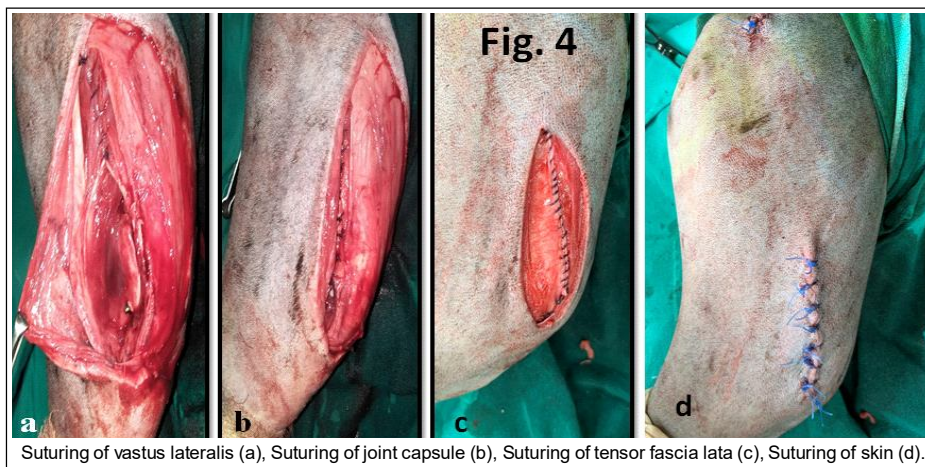


Fig 4: Sequential photographs of surgical wound closure.

significantly ( $p < 0.05$ ) less ( $2.00 \pm 0.82$  days) than group 2 ( $3.60 \pm 2.80$  days). Since, older fractures require breaking of callus and have muscle contracture with medullary canal filled with newly deposited callus, these were difficult to align and place pins in the medullary cavity. Therefore, end-threaded pinning was the preferred method in old cases.

The group 1 included 4 transverse (Fig 5a and b) and 6 oblique fractures, while group 2 included 4 transverse (Fig 7a and b), 4 oblique and one each of spiral and comminuted fracture (Fig 6a and b). There was no significant difference in the narrowest medullary canal diameter between the group 1 ( $9.29 \pm 3.13$  mm) and 2 ( $7.98 \pm 2.35$  mm).

Intraoperatively, in group 1, implant placement required significantly ( $p < 0.05$ ) more time ( $72.4 \pm 11.16$  min) than in group 2 ( $60 \pm 15.78$  min). Placements of two pins in group 1 could be the reason for the prolonged duration of surgery. Single pin fixation has been described as easy, less time consuming technique but is associated with more callus

formation and prolonged healing time in supracondylar femur fractures in dogs (Aithal *et al.*, 1998). The TENS placement was easy but reduction was difficult particularly in oblique femur fractures. A longer incision was required to expose the fracture site and femoral condyles for the placement of TENS.

Immediate postoperative radiographs showed comparable mean fracture reduction scores between the group 1 ( $1.30 \pm 0.95$ ) and 2 ( $1.20 \pm 0.63$ ). In group 2, the implant occupied non-significantly higher per cent of narrowest medullary canal diameter ( $64.31 \pm 9.15\%$ ) as compared to group 1 ( $46.28 \pm 13.56\%$ ). Radiographs made on day 12 (group 1) revealed clearly visible fracture line with uniform ( $n=8$ ), non-uniform ( $n=1$ ) or non-appreciable ( $n=1$ ) callus.

In group 2, 9 out of 10 dogs presented on day 12 revealed visibility of fracture line, with uniform ( $n=6$ ), non-uniform ( $n=1$ ) or no ( $n=3$ ) callus. Implant was stable in 7 out

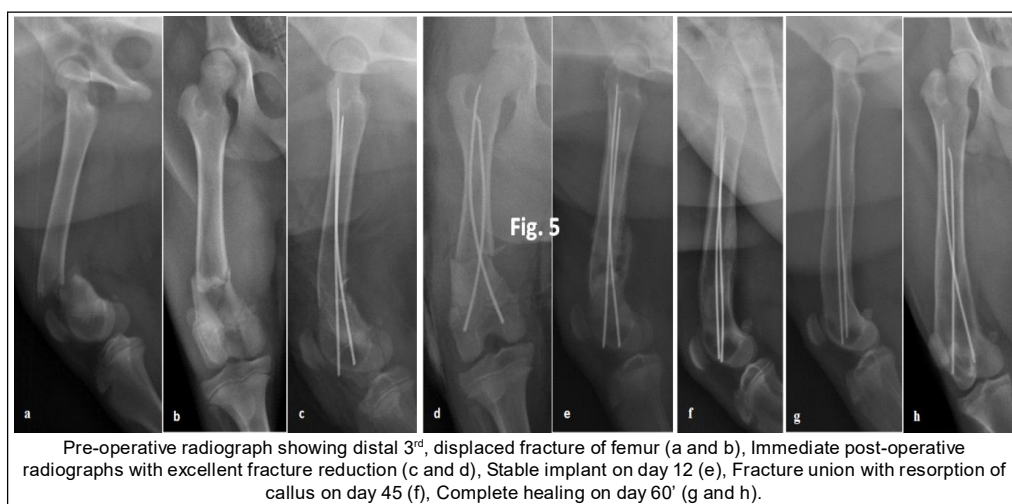


Fig 5: Sequential radiographs of fracture healing in group 1.

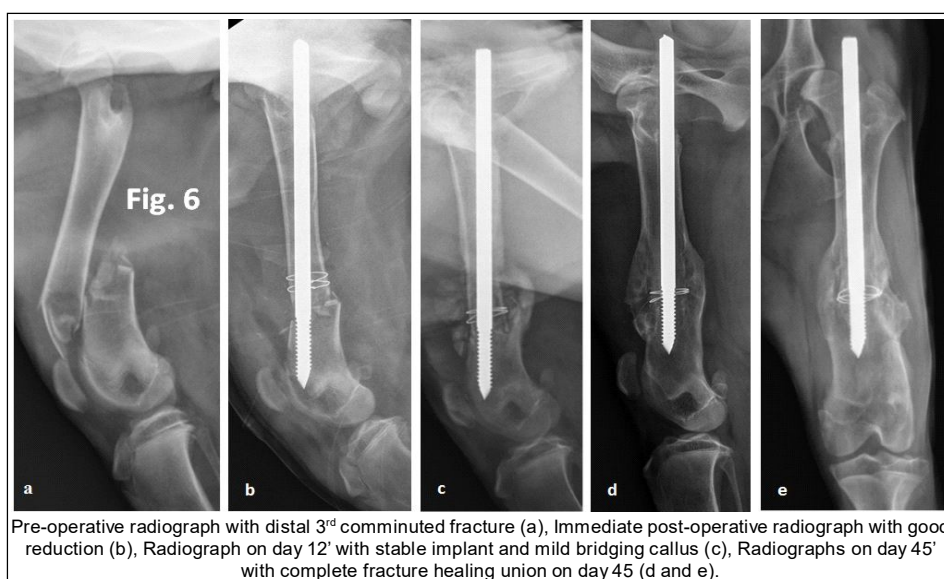


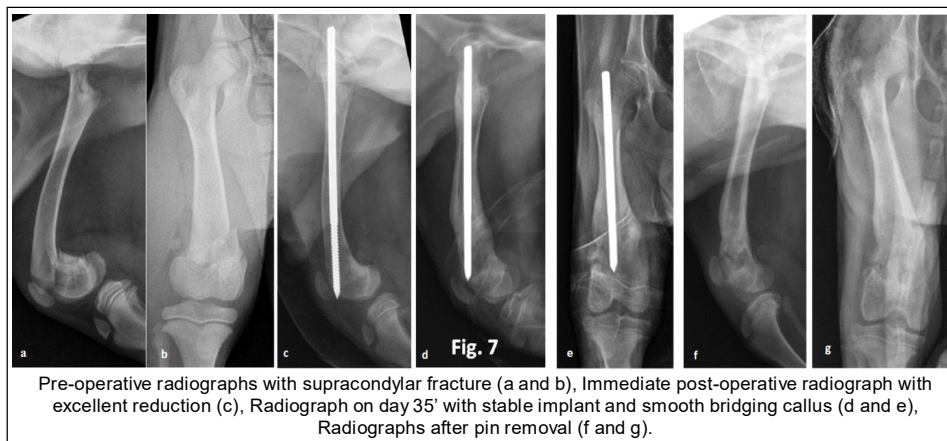
Fig 6: Sequential radiographs of fracture healing in group 2.

of 9, one had proximal pin migration (Fig 9) and another had fracture of cranial wall of distal bone fragment due to implant (Fig 7). Besides, two dogs had stifle joint effusions.

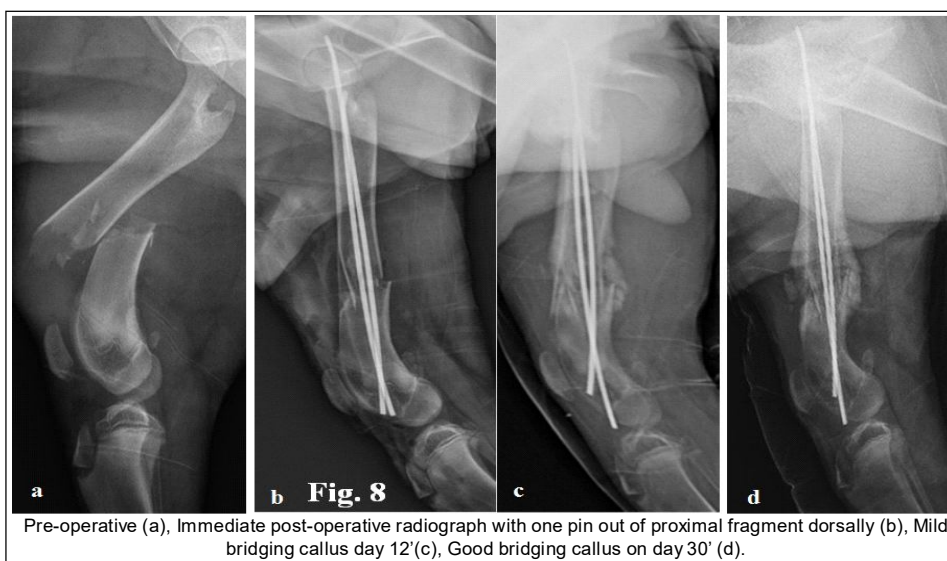
Irrespective of technique used, femur fractures had good callus formation by day 45 justifying faster healing of fracture in young dogs and early implant removal.

In group 1, the overall fracture alignment at 45<sup>th</sup> day was graded as excellent (2 cases), very good (3 cases) and

good (5 cases) and the per cent alignment grades were similar for group 2. The fracture line was visible in 3 and 2 dogs of groups 1 and 2, respectively. The overall callus was smooth in all the cases but not uniform with few sites having excess bridging callus showing remodeling with time. The stifle joint effusions were recorded in only one case of group 1 (due to distal pin migration) and 4 dogs of group 2 on day 45.



**Fig 7:** Sequential radiographs of fracture healing in Group 2.



**Fig 8:** Sequential radiographs in group 1.

**Table 1:** Comparison of bone length growth of operated and contralateral healthy limb.

Parameters/ group	Operated bone length (Day 0)	Contralateral healthy bone length (Day 0)	Operated bone length (Day 45)	Contralateral healthy bone length (Day 45)
Overall	167.60±29.71 (135-214)	170.40±31.33 (135-215)	184.12±24.01 (151-216)	193.75±30.75 (156-245)
Group 1	173.25±34.62 <sup>aa</sup> (144-214)	177.75±31.68 <sup>bb</sup> (149-215)	186.33±31.18 <sup>aa</sup> (151-210)	192.00±32.74 <sup>bb</sup> (156-220)
Group 2	163.83±28.76 <sup>aa</sup> (135-210)	165.50±33.06 <sup>bb</sup> (135-220)	182.80±22.74 <sup>aa</sup> (154-216)	194.80±33.40 <sup>bb</sup> (157-245)

aa': Significant difference in the length of operated femur length at day 0' and 45' at p<0.01 for both group 1 and 2.

bb': Significant difference in the length of contralateral healthy femur length at day 0' and 45' at p<0.01 for both group 1 and 2.

When two titanium elastic nails of same diameter are inserted in a dynamic cross intramedullary fashion, symmetrically, the biomechanical stability is achieved from the divergent 'C' configuration that creates six points fixation (3 point fixation with each nail) (Mahar *et al.*, 2004). To achieve this, the nails are pre-curved to approximately three times the narrowest (isthmus) diameter of bone. These nails reduce chances of angulation in both antero-posterior direction and varus/valgus by achieving axial and rotational stability (Singh *et al.*, 2006). In the current study, the TENS were not pre-curved but were bent at the distal ends before cutting extra pins that might have added to curvature of the TENS pins.

To assess femur bone length (operated and healthy) between days 0 and 45, statistical analysis using paired "t" test was performed. A significant difference in the bone length of operated and healthy femur was recorded on day 45 as compared to day 0, irrespective of the technique used (Table 1). It was inferred that the use of any fracture fixation technique such as end-threaded pin and TENS for femur lead to reduced bone growth as compared to the growth of contralateral healthy bone. This might be due to the fact that in distal third or supracondylar fractures of young dogs, the distal growth plate might have been damaged during trauma or with internal fracture fixation technique (Alcantara and Stead, 1975).

As compared to Group 2, the stifle joint ROM was significantly higher on day 12 ( $p < 0.01$ ) and day 60 ( $p < 0.05$ ) in group 1 (Table 2). The group 1 dogs had almost equal ROM of the operated stifle joint compared to the healthy contralateral joint. This could be due to better stability provided by TENS as compared to single end-threaded pin. In contrast, Gill *et al.* (2018) reported better functional outcome including ROM of stifle joint in supracondylar fracture repaired with end-threaded pin as compared to cross pinning. Interference of cross pin cut ends with soft tissue and stifle joint was explained as the reason.

During walking, the weight bearing scores in group 1, improved significantly ( $p < 0.01$ ) on day 45 as compared to day 12 (Table 3). Similarly, lameness score was found to be significantly ( $p < 0.05$ ) less on day 45 as compared to day 12 in group 1 (Table 4). These findings are explained due to better stability by TENS as compared to single end-threaded pin.

In group 1, all the dogs had full functional outcome, whereas in group 2, eight dogs had full functional outcome, while one each had acceptable and unacceptable. In group 1, 2 dogs had minor complication of distal and proximal pin migration which resumed normal walk after pin removal (Fig 8).

In group 2 also, minor complications ( $n=3$ ) of seroma formation ( $n=2$ , one had transient sciatic nerve deficit) (Fig 10) and proximal pin migration ( $n=1$ ) were recorded. All three dogs recovered completely. Sciatic nerve deficit in cases of supracondylar femur fractures repaired using retrograde end-threaded pins has been reported

**Table 2:** Goniometry findings (mean±SD) of femur fractures (ROM- Range of motion).

Parameter/ groups	Operated limb (Day 12)			Operated limb (Day 45)			Operated limb (Day 60)			Healthy limb (Day 60)		
	Flexion	Extension	ROM	Flexion	Extension	ROM	Flexion	Extension	ROM	Flexion	Extension	ROM
Overall	67.6±18.17	137.25±11.85	70.35±22.68	48.82±16.53	144.70±6.49	95.88±18.28	37.5±5.05	148.56±2.71	111.0±63.86	35.59±2.85	149.88±2.18	114.29±2.80
Group 1	57±13.82 <sup>ab</sup>	138.6±11.53	82.6±14.80 <sup>ab</sup>	42.33±9.53	142.22±7.55	99.89±13.35	35.2±3.68 <sup>ab</sup>	147.7±3.16	112.5±2.32 <sup>a</sup>	34.7±2.91	149.6±2.80	114.9±3.03
Group 2	78.2±16.01 <sup>ab</sup>	135.9±12.63	58.1±23.09 <sup>ab</sup>	56.13±20.15	147.5±3.78	91.38±22.73	41.33±4.89 <sup>ab</sup>	150±0	108.67±4.89 <sup>a</sup>	36.86±2.41	150.28±0.75	113.42±2.37

Values with same superscript show significant difference between each other at  $p < 0.05$  (single superscript) and  $p < 0.01$  (double superscript).

**Table 3:** Comparative weight bearing grades at different intervals in various groups.

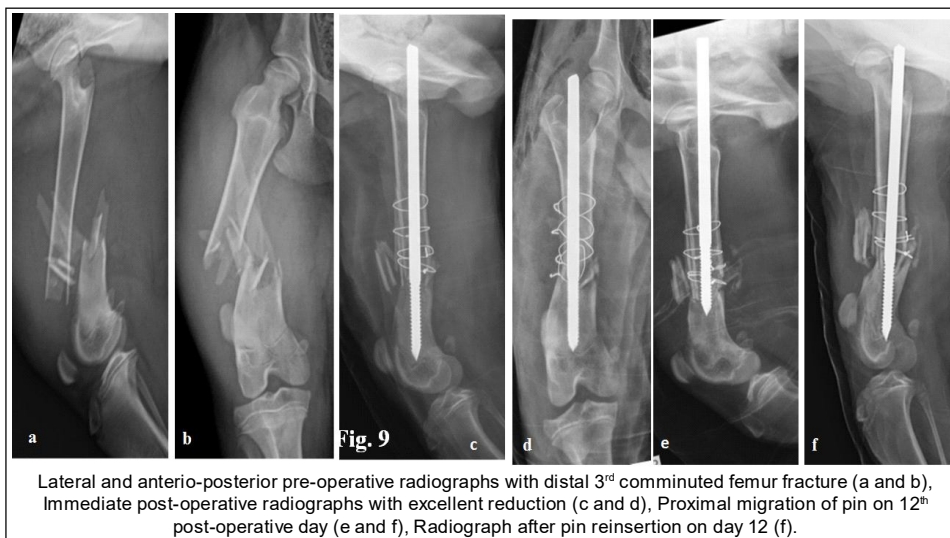
Parameter/ groups	Day 12		Day 45		Day 60		Day 90 and above	
	Standing (grades out of 2)	Walking (grades out of 4)	Standing (grades out of 2)	Walking (grades out of 4)	Standing (grades out of 2)	Walking (grades out of 4)	Standing (grades out of 2)	Walking (grades out of 4)
Overall	1.44±0.51	2.06±1.12	1.50±0.51	2.72±1.07	2±0	4±0	2±0	4±0
Group 1	1.62±0.52	1.75±1.04**	1.60±0.52	2.80±1.03**	2±0	4±0	2±0	4±0
Group 2	1.25±0.46	2.38±1.88	1.38±0.52	2.62±1.19	2±0	4±0	2±0	4±0

Values with same superscript (\*\*) showing significant difference at p<0.01.

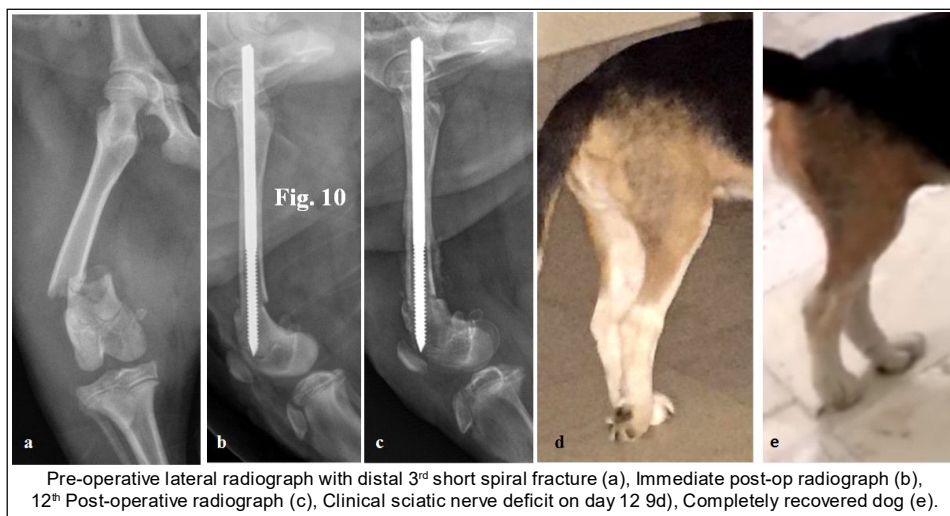
**Table 4:** Comparative lameness scores in femur fractures.

Group	Day 12	Day 45	Day 60 and above
Overall	3.44±1.09 (1-5)	2.28±1.87 (0-4)	0.33±0.82 (0-2)
Group 1	3.12±1.25* (1-4)	2±1.88* (0-4)	0
Group 2	3.75±0.88 (2-5)	2.62±1.92 (0-4)	0.67±1.1 (0-2)

Values with same superscript (\*) showing significant difference at p<0.05.



**Fig 9:** Sequential radiographs of dog in group 2.



**Fig 10:** Sequential radiographs in a beagle dog.

(Fortere *et al.*, 2007; Gill *et al.*, 2018). Therefore, normograde method of pinning has been recommended in femur fractures (Palmer *et al.*, 1988). Osteopenic dogs had been reported to have implant related complications (Kumar *et al.*, 2007), as also reported in one dog of group 2, in this study.

There is lack of published reports on the use of TENS of long bone fracture fixation in veterinary practice. This is the first report of its kind on the successful clinical use of TENS for the stabilization of femoral fractures in dogs.

## CONCLUSION

The Titanium Elastic Nailing System (TENS) provide better implant placement and overall functional outcome for the stabilization of supracondylar or distal third femur fractures in young dogs in comparison to stainless steel intramedullary pin. The TENS provide better functional outcome, minimal stiffness of stifle joint and early weight bearing in femur fracture young dogs.

## ACKNOWLEDGEMENT

Authors are thankful to SERB-DST (file no. CRG/2018/002997 dated 05.02.2019) and ICAR (All India network program on diagnostic imaging and Management of surgical conditions in animals) for providing partial financial support and Guru Angad Dev Veterinary and Animal Sciences, Ludhiana for providing facilities to conduct this research.

## REFERENCES

Aithal, H.P., Singh, G.R., Bisht, G.S. (1999). Fractures in dogs: A survey of 402 cases. *Indian Journal of Veterinary Surgery*. 20(1): 15-21.

Aithal, H.P., Singh, G.R., Sharma, A.K. (1998). Modified technique of single pin fixation and cross intramedullary pin fixation technique for supracondylar femoral fracture in dogs: A comparative study. *Indian Journal of Veterinary Surgery*. 19(2): 84-89.

Alcantara, P.J., Stead, A.C. (1975). Fractures of the distal femur in the dog and cat. *Journal of Small Animal Practice*. 16: 649-659.

Altunatmaz, K., Karabagli, M., Aydin, D., Guzel, O., Yalin, E.E., Ugurlu, U., Ekici, H. (2017). The treatment of supracondylar and diaphyseal femoral fractures in cats using intramedullary two-way stacked Kirschner wire application. *Turkish Journal of Veterinary and Animal Sciences*. 41(2): 282-287.

Bhaskar, A. (2005). Treatment of long bone fractures in children by flexible titanium elastic nails. *Indian Journal of Orthopaedics*. 39(3): 166-168.

Cook, J.L., Evans, R., Conzemius, M.G., Lascelles, B.D.X., McIlwraith, C.W., Pozzi, A., Stewart, A. (2010). Proposed definitions and criteria for reporting time frame, outcome and complications for clinical orthopedic studies in veterinary medicine. *Veterinary Surgery*. 39(8): 905-908.

Cook, J.L., Tomlinson, J.L., Reed, A.L. (1999). Fluoroscopically guided closed reduction and internal fixation of fractures of the lateral portion of the humeral condyle: Prospective clinical study of the technique and results in ten dogs. *Veterinary Surgery*. 28(5): 315-321.

Fortere, F., Tomek, A., Rytz, U., Brunberg, L., Jaggy, A., Spreng, D. (2007). Iatrogenic sciatic nerve injury in eighteen dogs and nine cats (1997-2006). *Veterinary Surgery*. 36: 464-471.

Gill, K.K., Kumar, A., Sangwan, V., Anand, A., Mahajan, S.K., Mohindroo, J. (2018). Comparative functional outcome of supracondylar femoral fracture stabilized with cross and end threaded intramedullary pinning in dogs. *Indian Journal of Animal Sciences*. 88(2): 161-169.

Johnson, K.A. (2014). *Piermattei's Atlas of Surgical Approaches to the Bones and Joints of the Dog and Cat* (No. 114). Elsevier Health Sciences.

Kaur, A., Kumar, A., Kumar, D., Mohindroo, J., Saini, N.S. (2015). Feasibility of C-arm guided closed intramedullary pinning for the stabilization of canine long bone fractures. *Veterinary World*. 8(12): 1410-1015.

Kaur, A., Kumar, A., Sangwan, V., Anand, A., Mahajan, S.K. (2016). Evaluation of end threaded intramedullary pinning for the stabilization of distal diaphyseal and supracondylar fractures in dogs. *Indian Journal of Veterinary Surgery*. 37(2): 105-108.

Kumar, A., Qureshi, V., Sangwan, V. (2020). Biological osteosynthesis in veterinary practice: A review. *International Journal of Livestock Research*. 10(10): 24-31.

Kumar, K., Mogha, I.V., Aithal, H.P., Kinjavdekar, P., Amarpal, Singh, G.R., Kushwaha, R.B. (2007). Occurrence and pattern of long bone fractures in growing dogs with normal and osteopenic bones. *Journal of Veterinary Medicine Series A*. 54(9): 484-490.

Mahar, A.T., Lee, S.S., Lalonde, F.D., Impelluso, T., Newton, P.O. (2004). Biomechanical comparison of stainless steel and titanium nails for fixation of simulated femoral fractures. *Journal of Pediatric Orthopaedics*. 24(6): 638-641.

Palmer, R.H., Aron, D.N., Purinton, P.T. (1988). Relationship of femoral intramedullary pins to the sciatic nerve and gluteal muscles after retrograde and normograde insertion. *Veterinary Surgery*. 17(2): 65-70.

Shires, P.K., Hulse, D.A. (1980). Internal fixation of physeal fractures using the distal femur as an example. *Compend Contin Educ Pract Vet*. 2: 854-861.

Singh, R., Sharma, S.C., Magu, N.K., Singla, A. (2006). Titanium elastic nailing in pediatric femoral diaphyseal fractures. *Indian Journal of Orthopaedics*. 40(1): 29-34.

Whitney, W.O., Schrader, S.C. (1987). Dynamic intramedullary cross pinning technique for repair of distal femoral fractures in dogs and cats: 71 cases (1981-1985). *Journal of the American Veterinary Medical Association*. 191(9): 1133-1138.