



Detection of group A rotavirus and histopathological studies in diarrheic piglets of Kamrup district, Assam

Seema Rani Pegu*, Dilip Kumar Sarma, Swaraj Rajkhowa, Manjisa Choudhury, Jyoti Prasad Das and Diganta Sarma

ICAR-National Research Centre on Pig,
Rani, Guwahati-781 131, Assam, India.

Received: 03-09-2015

Accepted: 22-10-2016

DOI: 10.18805/ijar.v0iOF.7655

ABSTRACT

Porcine group A rotavirus (PoRVA) is a major cause of neonatal diarrhea in suckling and recently weaned piglets worldwide. Rota viral diarrhoea is an important cause of morbidity and mortality in the neonates of pigs. The present study was carried out to determine the prevalence of rotavirus infection among piglets of organized and unorganized pig farms in Kamrup district of Assam. During the present study 107 diarrheic faecal samples from different pig farms of Kamrup district of Assam were collected. The collected samples were screened for the presence of rotavirus antigen by Immunochromatographic assay and RT-PCR. Of the 107 diarrheic samples, 20 (18.7%) were found to be positive for rotavirus Group A antigen by monoclonal based immunochromatographic assay. All the diarrheic samples found positive for the viral antigen by immunochromatographic assay were also analyzed by RT-PCR and 14 (13.1%) samples were found to be positive. The histopathological studies in the intestinal tissue samples of 12 piglets died of diarrhoea showed atrophy of villous in the small intestine along with sloughing of mucosae. Scanning Electron Microscopy analysis of intestinal tissues confirmed replication of rotaviruses in the villous enterocytes resulting in villous atrophy.

Key words: Diarrhoea, Histopathology, Immunochromatographic assay, PCR, Piglet, Rotavirus, SEM.

INTRODUCTION

Neonatal diarrhea is the most important health problem in suckling and freshly weaned piglets throughout the world (Tubbs *et al.* 1993). Neonatal diarrhea increases the morbidity and mortality rates in the maternity units and nurseries of pig farms worldwide, causing direct and indirect economic losses to the pig industry (Dewey *et al.* 1995, Wittum *et al.* 1995). Rotavirus infection is one of the foremost causes of viral enteritis in young pigs, especially in 1-4 weeks old piglets (Bohl, 1979). In the adult pigs, the rate of sero-conversion due to rotavirus infection is almost 100% (Malik *et al.* 2014)

Rotaviruses belong to the *Reoviridae* family and are characterized by double-stranded RNA (dsRNA) containing 11 genomic segments and by capsids composed of three concentric protein layers. Based on the antigenic properties of the capsid protein in the middle layer (VP6), rotaviruses are classified into 5 distinct groups (A to E), and two tentative species (F and G). Recently, a new group (H) was described by Matthijnsens *et al.* (2012). The A, B, C, and H rotavirus (RV) groups have been found in humans and animals, whereas groups D-G have been identified only in animals (Estes and Kapikian 2007). The rotavirus major inner capsid protein is VP6, which is the most abundant structural protein of rotavirus (>50% of total virion mass).

VP6 is highly antigenic and contains antigenic determinants shared by all group A rotaviruses and antigenic determinants unique to the subgroup specificity (Yuan *et al.* 2000). However, rotavirus group A (RVA) is the main group of rotaviruses that cause diarrhea in human (infants) and young animal hosts (Estes and Kapikian 2007).

Porcine group A rotavirus (PoRVA) infections are most frequently identified in episodes of diarrhea in piglets worldwide (Halaihel *et al.* 2010). In India, most of the records on RV epidemiology have originated from north-eastern part of the country where pig farming constitutes major share (40%) of pig population of the country and is directly related to the livelihood of poor farmers in general and tribal farmers in particular (Malik *et al.* 2014). The surveillance studies done in India from 1998 – 2013 on porcine rotavirus reported maximum prevalence (46.4%) in north-eastern region (Malik *et al.* 2014). There are several reports available on rotavirus associated piglet diarrhea in India including Assam (Jhala and Raghavan, 1998; Barman *et al.*, 2003; Bora *et al.*, 2007; Nath *et al.*, 2007; Kusumakar *et al.*, 2008; Dubal *et al.*, 2013; Das *et al.*, 2016). Rotavirus infection is primarily restricted to the villous epithelium of the small intestine (Ciarlet *et al.* 2002). The virus replication in the villous enterocytes results in cell lysis, villous blunting and atrophy along with the loss of intestinal absorptive cells. The degree of villous atrophy

*Corresponding author's e-mail: drseemapegu@yahoo.com

#These authors contributed equally to this study.

and the distribution of atrophic villi in the small intestine depend on the age of the pig and serogroup (Zimmerman *et al.* 2012). Reports available on examination of the small intestine by scanning electron microscopy had indicated extensive degeneration and desquamation of epithelial cells with villi stripped and shortened (Narita *et al.* 1982, Torres-Medina *et al.* 1980) and nearly all degenerated enterocytes had sparse microvilli and were partially detached from each other and the villus lamina propria (Stevenson, 1990). The evolution of porcine RVs, especially through the exchange of genomic segments among the different host specific RVs, leads to emergence of novel porcine strains having the capability to infect human beings highlights their potential of zoonotic infection (Malik *et al.* 2014).

The aim of this study was to detect the prevalence of rotavirus group A infection in piglets having the symptoms of diarrhoea in Kamrup districts of Assam and to determine the histopathological changes in the tissues of the small intestine of the piglets died of diarrhoea.

MATERIALS AND METHODS

Faecal samples: This study comprised of sampling of total 107 diarrheic faecal samples with a watery consistency from suckling (\leq 3-week-old) piglets from organized and unorganized piggery farms located in different parts of Kamrup districts (rural and metro), Assam. Faecal samples were collected per rectally from diarrheic piglets and placed in labeled sterile plastic tubes. All the samples were transported to the laboratory on ice. Thirty percent faecal suspensions (liquid faeces (v/v), semi-solid faeces (w/v)) were prepared in 0.01 M phosphate-buffered saline (PBS) (pH 7.4) containing 0.01 mM calcium chloride. The suspensions were stored at -20°C .

Immunochromatographic Assay (ICA): ROTACROM (INGEZIM) was used for the detection of group A rotavirus in faecal samples according to the manufacturer's instructions. The ROTACROM kit used was based on an immunochromatographic technique, using a monoclonal antibody specific for Rotavirus conjugated to latex particles. Samples were prepared by introducing swaps into the faecal sample. Five drops of the prepared sample was added into the sample window. The result of the assay is interpreted by the appearance of blue and purple lines in the window. The appearance of purple line on the window-T and a blue line on the window- C confirms the sample to be positive for group A rotavirus. Presence of only blue line in the window- C considered the sample as negative and the assay is invalid if no blue line appears on the window-C.

Viral RNA Isolation: Viral RNA was extracted from the samples found positive for rotavirus group A antigen by ICA using TRIzol Reagent (Invitrogen Co.) according to manufacturer's instructions. Quality check and quantification was done by gel electrophoresis (1.5% formaldehyde

Agarose gel) and eppendorf BioPhotometer plus at optical density (OD) 260nm/280nm respectively.

RT-PCR: RT-PCR was carried out using a Thermo Scientific RevertAid First Strand cDNA Synthesis Kit (#K1621, #K1622) according to the manufacturer's instructions. The prepared cDNA was either stored at -20°C or amplified immediately. A pair of specific published primer for the segment 6 region of group A rotavirus was used to amplify the cDNA. The sequence for forward and reverse primer used was 5'-AAAGATGCTAGGGACAAAATTG- 3' (rot 3) and 5'- TTCAGATTGTGGAGCTATTCCA - 3' (rot 5) respectively (Song *et al.* 2014). The RT-PCR was carried out with a slight modification of Song *et al.* 2014 in the preparation of RT-PCR protocol. The RT-PCR was performed in a 50 μl volume reaction and in each reaction mixture 6 μl of cDNA as template was added to 5 μl of 10X DreamTaq PCR buffer, 1 μl 10mM dNTPs, 1 μl of each forward and reverse primer (10pmole each), 5 units of DreamTaq DNA polymerase and final volume was made to 50 μl using nuclease free water. For amplification the thermal cycler was programmed according to RT-PCR conditions cited by Song *et al.* 2014. The PCR amplicon was checked for the presence of 309bp product specific for segment 6 region of group A rotavirus by electrophoresing in 1.5% Agarose gel. 100bp ladder was used as marker and Ethidium bromide as tracing dye under UV illuminator. Positive and negative controls were used for the validation of the RT-PCR.

Histopathology studies: Detailed post-mortem examination was conducted on 12 dead piglets having history of diarrhoea and gross pathological changes observed in different organs were systematically recorded. Tissue samples were collected mainly from the small intestine and preserved in 10% formalin solution for routine histopathological examination. After proper fixation the tissues were processed, embedded in paraffin and 4-5 μ thick sections were made and stained with Haematoxylin and Eosin for histopathological studies. **Scanning Electron Microscopy (SEM):** Intestinal tissues were selected for SEM analysis only from the dead piglets found positive for rotavirus group A antigen by ICA. The intestinal tissues were fixed in 2.5% Glutaraldehyde and 0.1M Cacodylate buffer and subjected for SEM at SAIF, NEHU Shillong.

RESULTS AND DISCUSSION

Molecular detection of group a rotavirus by Immunochromatographic Assay and RT-PCR: A total of 107 diarrheic faecal samples were tested for RVA both by ICA and RT-PCR techniques. 20 samples (18.7%) were found positive for RVA group A antigen in ICA and 14 (13.1%) samples were found positive for the virus in the RT-PCR. Fig.1 shows faecal sample positive for Group A Rotavirus detected by ROTACROM ICA kit. The 14 samples showed positivity to 309bp product of segment 6 region of group A

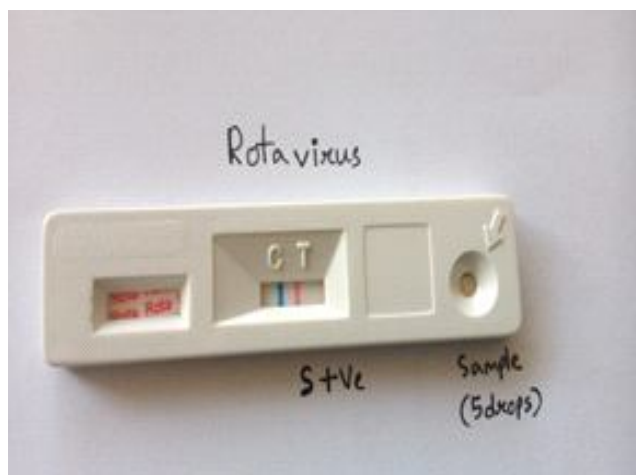
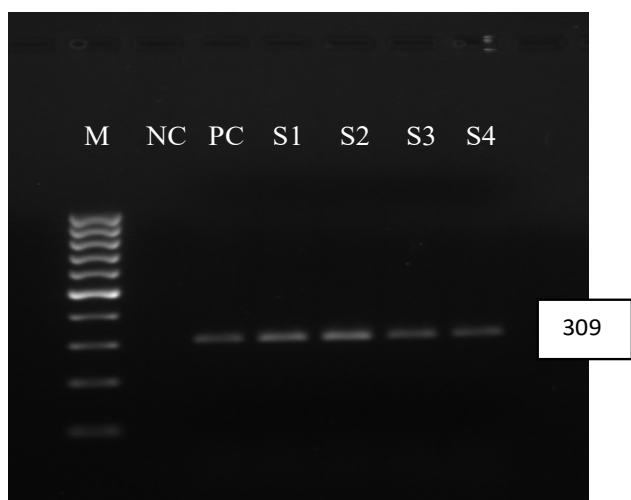


Fig 1: Faecal sample showing positive for Group A Rotavirus by ROTACROM Immunochromatographic assay

rotavirus. A typical PCR banding pattern in Fig.2 shows 309bp amplicon confirming the presence of segment 6 region of group A rotavirus.

Histopathological studies: The post mortem examination of the piglets revealed thin walled mucosae of the small intestine with yellowish watery fluid in the lumen. The histopathological lesions recorded in the present study were sloughing of the intestinal mucosa and the loss of enterocytes was extensive enough to cause a reduction in villous length, also known as villous atrophy (Fig.3).

Scanning Electron Microscopy (SEM): Scanning Electron Microscopic analysis of intestinal tissues confirmed replication of rotaviruses in the villous enterocytes resulting in villous atrophy with extensive degeneration and detachment of enterocytes (Fig. 4a and 4b).



(M : 100bp marker; NC : negative control; PC : positive control; S1,S2,S3,S4 : faecal samples positive for rotavirus group A)

Fig 2: PCR products of 309bp confirming the presence of segment 6 region of Group A Rotavirus

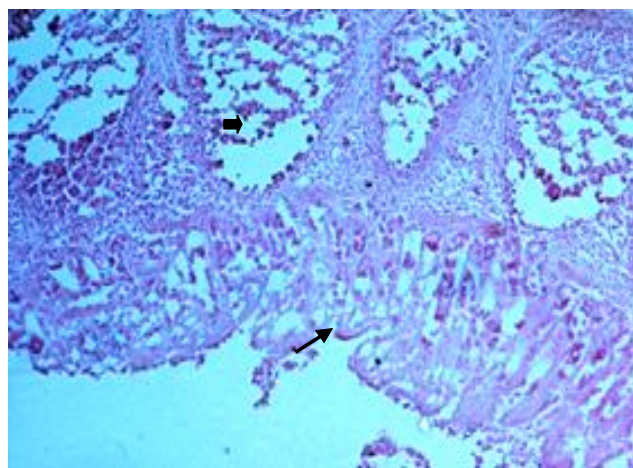


Fig 3: Depletion of lymphocytes in the lymphoid follicles (■) and villous atrophy (↘) in the small intestine H&E (20x)

The present study comprised of sampling of total 107 diarrheic faecal samples with a watery consistency. The faecal samples were tested for the presence of RVA both by ICA and RT-PCR. 18.7% of the faecal samples were found positive for RVA group A antigen in ICA and 13.1% samples were found positive for the virus in the RT-PCR. Negative controls were included in every reaction to monitor false-positive results. Of late, RT-PCR has been proved to be a powerful, sensitive and robust tool for RV detection, particularly for RVA infections (Kattoor *et al.* 2014). The ROTACROM ICA kit used in the present study for the detection of group A rotavirus in faecal samples is based on an immunochromatographic technique, using a monoclonal antibody specific for Rotavirus conjugated to latex particles. The monoclonal antibody based ICA is an attractive diagnostic tool for routine screening because of its one-step rapid detection, simplicity and the test can be run individually with the results confirmed less than 30 min. Conveniently, the assay does not require a complicated step to clean up samples or purification of samples before analysis and has a shorter test time than virus isolation. Although the technique is a qualitative detection, it provided an effective means of evaluating the presence of rotavirus group A antigen in faecal samples. However, six faecal samples confirmed positive in the ROTACROM ICA were found negative by the RT-PCR in our study. This would suggest a false positive result by ICA since very weak positive band intensity was observed in these six samples by ICA. The discordant rate (5.6%) between ICA and RT-PCR was similar to that reported in previous studies on rotavirus by Kim *et al.* (2014).

Rotaviruses replicate in the non-dividing mature enterocytes near the tips of the villi, suggesting that differentiated enterocytes express factors required for efficient infection and replication (Ramig, 2004). The histopathological lesions and SEM image reported in our study confirms that group A rotavirus replication in the villous enterocytes resulted in cell lysis thereby, villous blunting





Fig 4a: Blunting of tip of the villi in small intestine of a piglet with Rota virus infection in Scanning electron microscopy (SEM)



(Bar=100µm), Fig. 4b : Atrophy of villi with extensive degeneration and detachment of enterocytes (Bar=10 µm)

and atrophy along with the loss of intestinal absorptive cells. This observation also agrees with the widely accepted mechanism of rotavirus-induced villous atrophy with loss of intestinal absorptive cells, which causes malabsorption and thus resulting in diarrhea in pigs and humans (Zimmerman *et al.* 2012).

In conclusion, the present study indicated a high prevalence (18.7% by ICA and 13.1% by RT-PCR) of group A rotavirus infection in piglets of the Kamrup districts of Assam. The histopathological study and SEM analysis confirmed replication of rotaviruses in the villous enterocytes resulting in villous atrophy. Although rotavirus

is an established pathogen associated with diarrheic condition of humans and animals, the rotavirus infection of pigs is also having zoonotic importance. Considering the prevalence of rotavirus in the present study warrants awareness amongst the pig rearers, improvement in management practices and strategies to control the rotavirus infection.

ACKNOWLEDGEMENT

The authors acknowledged the financial support received from DBT, Govt. of India in the form of ADMaC project and the Director ICAR-NRC on Pig, Rani, Guwahati for providing facilities to carry out the work.

REFERENCES

- Barman, N.N., Barman, B., Sarma, D.K. and Pensaert, M.B. (2003). Prevalence of rotavirus, transmissible gastroenteritis virus and porcine epidemic diarrhea virus antibodies in pigs of Assam, India. *Indian Journal of Animal Sciences*. **73**: 576-578.
- Bohl, E.H. (1979). Rotaviral diarrhea in pigs: Brief review. *J Am Vet Med Assoc*. **174**:613-615
- Bora, D.P., Barman, N.N. and Bhattacharyya, D.K. (2007). Isolation of rotavirus in MA 104 cell line from diarrhoeic piglets of Assam. *Indian Journal of Virology*. **18**: 40-43.
- Ciarlet, M., Conner, M.E., Finegold, M.J. and Estes, M.K. (2002). Group A Rotavirus infection and age-dependent diarrheal disease in rats: a new animal model to study the pathophysiology of rotavirus infection. *Journal of Virology*. **76**: 41-57.
- Das, S. and Handique, P.J. (2016). Isolation of field strains of Porcine Group A Rotavirus associated with piglet diarrhoea in north-east India, fostered in MA-104 cell line. *Animal Science Reporter*. **2**: 72-80
- Dewey, C.E., Wittum, T.E., Hurd, H.S., Dargatz, D.A. and Hill, G.W. (1995). Herd and litter-level factors associated with the incidence of diarrhea morbidity and mortality in piglets 4-14 days of age. *J Swine Health Prod*. **3**:105-112.
- Dubal, Z.B., Bhilegaonkar, K.N., Barbuddhe, S.B., Kolhe, R.P., Kaur, S., Rawat, S., Nambiar, P. and Karunakaran, M. (2013). Prevalence and genotypic (G and P) determination of porcine group A rotaviruses from different regions of India. *Tropical Animal Health and Production*. **45**: 609-15.
- Estes, M.K. and Kapikian, A. (2007). Rotaviruses. In D.M. Knipe, P.M. Howley, eds. *Fields virology*, 5th ed. Philadelphia : Lippincott Williams and Wilkins. 1917-1974.
- Halaihel, N., Masia, R.M., Fernandez-Jimenez, M., *et al.* (2010). Enteric calicivirus and rotavirus infections in domestic pigs. *Epidemiol Infect*. **138**: 542-548
- Jhala, M.K. and Raghavan, R. (1998). Detection and isolation of porcine rotavirus from diarrheic piglets. *Indian Journal of Virology*. **14**: 37-39
- Kattoor, J.J., Malik, Y.S., Kumar, N., Sharma, K., Sircar, S., Batra, M., Dhama, K. and Singh, R.K. (2014). Development of VP6 gene specific reverse transcription (RT)-PCR assay for detection of avian Group D Rotavirus in diarrheic chickens. *J Vet Sci Med Diagn*. **3**:3.

- Kim, J., Kim, H.S., Kim, H.S., Kim, J.S., Song, W., Lee, K.M., Lee, S., Park, K.U., Lee, W. and Hong, Y.J. (2014). Evaluation of an Immunochromatographic Assay for the Rapid and Simultaneous Detection of Rotavirus and Adenovirus in Stool Samples. *Annals of Laboratory Medicine*. **34** : 216-222.
- Kusumakar, A.L., Savita, Malik, Y.P.S., Minakshi and Prasad, G. (2008). Occurrence of mammalian group A rotavirus in swine population of central India. *Indian Journal of Animal Sciences*. **78**: 475-477.
- Malik, Y.S., Kumar, N., Sharma, K., Sircar, S., Dhama, K., Bora, D.P., Dutta, T.K., Prasad, M. and Tiwari, A.K. (2014). Rotavirus diarrhea in piglets: A review on epidemiology, genetic diversity and zoonotic risks. *Indian Journal of Animal Sciences*. **84**: 1035–1042.
- Matthijnssens, J., Otto, P., Ciarlet, M., Desselberger, U., Ranst, M.V. and Johne, R. (2012). VP6 sequence-based cut-off values as a criterion for rotavirus species demarcation. *Arch. Virol.* **157**:1177-1182.
- Narita, M., Fukusho, A., Konno, S. and Shimizu, Y. (1982). Intestinal changes in gnotobiotic piglets experimentally inoculated with porcine rotavirus. *Natl. Inst. Anim. Health Q* (Tokyo), Summer; **22**:54-60.
- Nath, A.J., Barman, N.N. and Das, S.K. (2007). Faecal excretion of rotavirus in naturally infected pigs: an epidemiological study. *Indian Journal of Animal Sciences*. **77**: 859-861
- Ramig, R.F. (2004). Pathogenesis of intestinal and systemic rota virus infection. *Journal of Virology*. 10213–10220.
- Song, D.S., Kang, B.K., Oh, J.S., Ha, G.W., Yang, J.S., Moon, H.J., Jang, Y.S. and Park, B.K. (2006). Multiplex reverse transcription-PCR for rapid differential detection of porcine epidemic diarrhea virus, transmissible gastroenteritis virus, and porcine group A rotavirus. *J Vet Diagn Invest*. **18**:278–281.
- Stevenson, W.G. (1990). Pathogenesis of a new porcine serotype of group A rotavirus in neonatal gnotobiotic and weaned conventional pigs. Iowa State University.
- Torres-Medina, A. and Underdahl, N.R. (1980). Scanning electron microscopy of intestine of gnotobiotic piglets infected with Porcine Rotavirus. *Can. J. comp. Med.* **44**: 403-411.
- Tubbs, R.C., Hurd, H.S., Dargatz, D.A. and Hill, G.W. (1993). Prewaning morbidity and mortality in the United States swine herds. *Swine Health Prod.* **1**:21–28.
- Wittum, T.E., Dewey, C.E., Hurd, H.S., Dargatz, D.A. and Hill, G.W. (1995). Herd and litter-level factors associated with the incidence of diarrhea morbidity and mortality in piglets 1–3 days of age. *J Swine Health Prod.* **3**:99–104.
- Yuan, L., Geyer, A., Hodgins, D.C, Fan, Z., Qian, Y., Chang, K., Crawford, S.E., Parren, V., Ward, L.A., Estes, M.K., Conner, M.E. and Saif L.J. (2000). Intranasal administration of 2/6-Rotavirus-like particles with mutant *Escherichia coli* heat-labile toxin (LT-R192G) induces antibody-secreting cell responses but not protective immunity in gnotobiotic pigs. *Journal of Virology*. **74**: 8843–8853.
- Zimmerman, J.J., Karriker, L. A., Ramirez, A., Schwartz, K.J. and Stevenson, G.W. (2012). Diseases of Swine, Chapter 43 Reoviruses (Rotaviruses and Reoviruses). 10th Ed., John Wiley & Sons, Inc., U.K. 621-630