



Fibrinous Pericarditis and its Surgical Management in Cattle

D.R. Manjunatha, R.V. Suresh Kumar, B.N. Nagaraja, P. Veena,
P. Jagapathiramayya, Ch. Srilatha

10.18805/IJAR.B-4761

ABSTRACT

Background: Traumatic pericarditis is one of the major problems encountered in cattle resulting in greater economic loss to the farming community and causes mortality. Diagnosis of heart diseases in animals is a challenging job for Veterinarians, bovines ingest foreign bodies (nails, thorns, glass pieces, metal wires, etc.) along with the feed and fodder which intern entangled in reticulum leading to traumatic pericarditis. The affected cattle shows drop in milk yield, sometimes death of affected animals especially pregnant or milking. The main aim of present study enlightens on diagnosis and surgical management of fibrinous pericarditis.

Methods: The clinical cases presented to Veterinary College Hospital, Hassan, suspected for pericarditis were selected for the present study, these animals were subjected for clinical, haemato-biochemical, ECG, radiological and ultrasonographic examination. In the total of 38 animals, six cattle were diagnosed as fibrinous pericarditis were subjected for pericardiotomy. Post operatively parenteral antibiotic and supportive therapy was given for 5-7 days.

Result: 5th rib resection followed by pericardiotomy gave favourable result in animals suffering with fibrinous pericarditis. So early detection timely employment of suitable surgical technique can prolong the life of animal and can save the life of the young one.

Key words: Brisket, Fibrinous pericarditis, Pericardiotomy, Submandibular edema.

INTRODUCTION

Pericarditis is an inflammation of the pericardium with an accumulation of serous or fibrinous exudates. It is often attributable to reticular foreign bodies which penetrate the reticular wall, diaphragm and pericardial sac Radostits *et al.* (2007). Pathognomonic clinical signs are tachycardia, muffled heart sounds, asynchronous heart sounds such as rubbing or splashing sounds, jugular vein distension and brisket edema Braun *et al.* (2007).

The diagnosis of pericarditis in cattle is generally based on signs, clinical examination, pericardiocentesis, ultrasonography and thoracic radiography Imran *et al.* (2011). However, ultrasonography is still the method of choice for detecting characteristics of reticular motility, fibrinous deposits and abscessation which cannot be determined using radiography. Based on ultrasonographic finding pericarditis can be classified into serous pericarditis, suppurative pericarditis, fibrinous pericarditis and constrictive pericarditis Manjunatha *et al.* (2018). In the majority of cases, massive fibrinopurulent adhesions obscure the cardiophrenic angle, cardiac silhouette and ventral diaphragm Echogenic deposits and strands of fibrin are seen on the epicardium and the ventricles are compressed by the effusion Abdelaal *et al.* (2009). The present paper emphasises on clinico diagnostic studies and its management of fibrinous pericarditis in cattle.

MATERIALS AND METHODS

The study was conducted in the Department of Veterinary Clinical Complex, Veterinary College, Hassan during the year 2018-2020. Animals from Hassan region and its surrounding areas were selected for the study. A total of thirty eight cattle

Department of Veterinary Clinical Complex, Veterinary College, Karnataka Veterinary, Animal and Fisheries Sciences University, Hassan-573 202, Bidar, Karnataka, India.

Corresponding Author: D.R. Manjunatha, Department of Veterinary Clinical Complex, Veterinary College, Karnataka Veterinary, Animal and Fisheries Sciences University, Hassan-573 202, Bidar, Karnataka, India. Email: manjuvet328@gmail.com

How to cite this article: Manjunatha, D.R., SureshKumar, R.V., Nagaraja, B.N., Veena, P., Jagapathiramayya, P. and Srilatha, C. (2022). Fibrinous Pericarditis and its Surgical Management in Cattle. Indian Journal of Animal Research. DOI: 10.18805/IJAR.B-4761.

Submitted: 25-08-2021 **Accepted:** 13-12-2021 **Online:** 04-03-2022

brought to Teaching Veterinary Clinical Complex (TVCC), Hassan with the history of anorexia, brisket /jowl /ventral edema and pyrexia, jugular pulsation and cording were included in the study (Fig 1). Six cases of fibrinous pericarditis were selected and treated by 5th rib resection followed by pericardiotomy and outcome of the study was described.

Haematology and biochemistry

Five milliliters of venous blood was collected in vacutainer tubes containing ethylene diamine tetra acetate (EDTA K3) as anticoagulant for haematological investigation and clot activator biochemical investigation. The parameters including packed cell volume (PCV), haemoglobin (Hb), red blood cell (RBC), white blood cell (WBC) and differential counts (DC) were analyzed as per the manufacturer's instructions using Automated hematology analyser, ERMA Inc. Pvt. Ltd. (Jain, 1986). The biochemical parameters includes ALT (IU/dL), AST (IU/dL), Glucose (mg/dL), Plasma fibrinogen (g/dl), Total protein (g/dl), Albumin (g/dl), Globulin

(g/dl), Sodium (mEq/mL), Potassium (mEq/mL) and Chloride (mEq/mL) were analyzed as per the manufacturer's instructions using semi automated biochemical analyser, SWEMED Inc, Pvt. Ltd. (Jain, 1986). Reference normal values were obtained from Radostits *et al.* (2007).

Based on inclusion and exclusion criteria, clinical signs, ECG, radiography and ultrasonography six animals of fibrinous pericarditis were selected for the study. Among six animals, five animals were female and one male belonging to different breeds like Amritmahal (01), HF cross breed (03) and Jersey cross breed (02) cattle's (Table 1). These animals had the history of fever, decreased milk yield, dullness, exercise intolerance, coughing, anorexia, recurrent bloat, submandibular and brisket edema.

All the cases suspected to have pericarditis were subjected for basic electrocardiographic examination to assess the status of cardiac function employing base-apex lead system. Using ECG machine (BPL medical Cardiant 3 channel ECG machine). The right arm lead was placed on the neck, the left arm lead on the chest wall just above the sternum and the neutral lead on the withers. The changes were only recorded when the heart rate was in the resting range and when the cows were standing on a rubber mat with paper speed of 25 mm per sec and amplitude of one cm equal to one mV, was recorded as per the procedure described by Tharwat (2011).

Left latero lateral radiography of the caudoventral thorax and reticulum in standing position was performed in all the cattle as described by Braun (2009) using Allengers X-ray machine. The radiographic exposure factors of 90-100 kVp, 40-60 mAs and source image distance of 90 cm were employed. Computerized radiographic processes were made by using AGFA computerized radiographic unit. The radiographs were described based on presence or absence of radiopaque foreign body.

All the animals were restrained in standing position in a crate and thoracoabdominal region was shaved, washed, cleaned and transmission gel was applied liberally for optimal transmission of sound waves. Heart was examined by scanning both sides of the costal part between four and fifth intercostals space by 3-5 MHz curvilinear ultrasonic transducer as per Braun *et al.* (2001). Ultrasound guided pericardiocentesis was performed and pericardial fluid was subjected for culturing and antibiotic sensitivity testing.

Based on clinical, electrocardiographic, radiological and ultrasonographic study confirmed cases of fibrinous pericarditis were subjected for 5th rib resection followed by pericardiotomy. The skin incision was made from the costochondral junction to a point 25 cm dorsally on a line over the 5th rib (Fig 2), the latissimus dorsi and serratus ventralis muscle were incised to expose the rib. Then the periosteum over the rib was incised and it was elevated with curved periosteal elevator to expose the rib. The rib was transacted by using Gigli wire saw at the proximal aspect of the incision (Fig 3) and disarticulated at the costochondral junction (Fig 4) and the portion of the rib was discarded (Anteneh and Ramswamy, 2015). The incision was then continued through the exposed periosteum and parietal pleura and after isolation of pericardium. The pericardium was incised and pericardial fluid was drained out using suction apparatus (Fig 5), then pericardial incision was extended to pass the hand into the pericardium to search foreign bodies and to break of adhesions between pericardium and epicardium. The pericardial sac was flushed with two litres warm normal saline and metronidazole solutions. The Foleys catheter no 18G was placed into pericardial space. The pericardial incision was closed with simple continuous suture using No. 2 polyglactin 910 (Vicryl[®] Johnson and Johnson Intl). Parietal pleura, periosteum and intercostal muscles were re-apposed employing ford interlocking suture using No. 2 chromic catgut (TRUGUT[®] manufactured by Suture India Pvt. Ltd). Skin incision was closed with cross mattress suture using monofilament polyamide size 1 (TRULON[®] Suture India Pvt. Ltd) and foleys catheter was fixed to skin (Fig 6) (Dehghani and Molaei, 1999, Gavali *et al.* (2003). Postoperatively pericardial cavity was flushed with 2 litres of warm normal saline followed by 200 ml of metronidazole once daily for five days through foleys catheter. The bovines which had radiographic foreign body in the reticulum, rumenotomy was performed under left paravertebral nerve block Tranquilli *et al.* (2007) and foreign bodies were retrieved (Fig 7) employing standard surgical procedure.

Post operatively parenteral antibiotics were selected based on ABST (Antibiotic sensitivity testing) report, supportive therapy like B-complex 10 ml intra muscularly, diuretics like frusemide 2mg/kg body weight intra muscularly and fluid therapy is infused at the rate of 20 ml per kg body weight per day was given for three days (Fig 8).

Table 1: Signalment and anamnesis of fibrinous pericarditis in six cattle under study.

Case no.	Breed	Age	Gender	Physiological status	Brisket edema	Submandibular edema	Abduction of elbow	Jugular pulsation
1	Holstein friesian cross breed	4 years	Female	Non pregnant	+++	+++	+++	++
2	Holstein friesian cross breed	4.6 years	Female	15 days after calving	+++	+++	+++	+++
3	Holstein friesian cross breed	6.6 years	Female	Eight months pregnant	++	+	++	++
4	Amruthmahal	3.5 years	Male	NA	++	+	+	+
5	Jersey cross breed	4 years	Female	Seven months pregnant	+++	++	++	++
6	Jersey cross breed	3.6 years	Female	one month after calving	+++	++	+++	+++

RESULTS AND DISCUSSION

Clinical examination of cattle affected with fibrinous pericarditis revealed brisket and submandibular edema, bilateral jugular pulsation, cording of jugular vein, reluctant to move downwards, arched back, abducted elbow, tachycardia and muffled heart sound were pathognomonic sign in diagnosing fibrinous form of pericarditis. Similar observations were made by Imran *et al.* (2011), Tharwat (2011) Ashwani Kumar *et al.* (2012) and Anteneh and Ramaswamy (2015).

The haematological evaluation of these cases revealed decreased hemoglobin and moderately increased total leukocyte count with shift to left. The biochemical values like protein albumin and plasma fibrinogen were slightly elevated than normal (Table 2). Decreased hemoglobin and moderately increased total leukocyte count with shift to left might be due to toxæmic condition of the body Manjunatha *et al.* (2018). Increased values of protein albumin and plasma fibrinogen in the present study was in accordance with the Athar *et al.* (2012), Hussein and Staufenberg (2014) and Manjunatha *et al.* (2018). Statistical analyses of collected data were analyzed by one-way ANOVA, using computer based SPSS statistics software 15.0 version following Duncan's Post Hoc.

Electrocardiography showed non-significant increase in the heart rate, increased P-R interval and decreased QRS

complex. These observations were in accordance with Tharwat (2011) and Athar *et al.* (2012).

Radiological examination aimed at localizing the foreign bodies. Out of six animals two animals did not reveal radioopaque foreign body and four animals showed presence of radioopaque foreign body in the reticulum (Fig 9). The radiography was helpful in finding of radioopaque foreign body in reticulum or thorax. Radiological characteristic of pericarditis affected animals is in correlation with the Sasikala *et al.* (2018) and Premkumar *et al.* (2019).

Cardiac ultrasonography was performed in a larger area extended from 3rd to 5th intercostal space on both left and right side. Ultrasonography revealed hypoechoic areas with echogenic deposits suggestive of strands of fibrin interspersed in between the pericardial sac and in some cases strands of fibrin were seen floating in the fluid between the epicardium and pericardium. Thick echogenic pericardial membrane was surrounding the heart with echogenic bands between them. The heart chambers were moderately compressed and pericardial depth varied from 2.3 to 6.2 cm (Fig 10 and Table 3). These findings were in accordance with earlier authors (Buczinski 2010, Imran *et al.* (2011), Tharwat (2011), Ashwani Kumar *et al.* (2012) Athar *et al.* (2012), Attia (2016), Ibrahim and Gomaa (2016), Khalphallah *et al.* (2017), Sasikala *et al.* (2018) and Premkumar *et al.* (2019).



Fig 1: Cattle with submandibular and brisket edema.

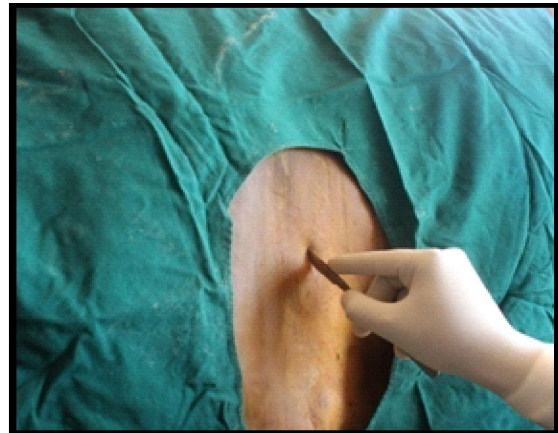

Fig 2: Skin incision for thoracotomy and pericardiotomy.

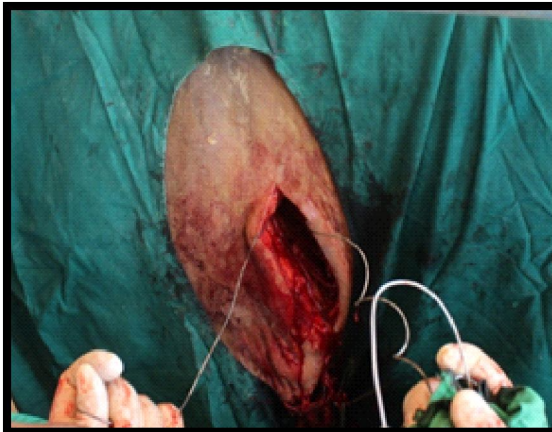


Fig 3: Transaction of rib by gigli wire saw.

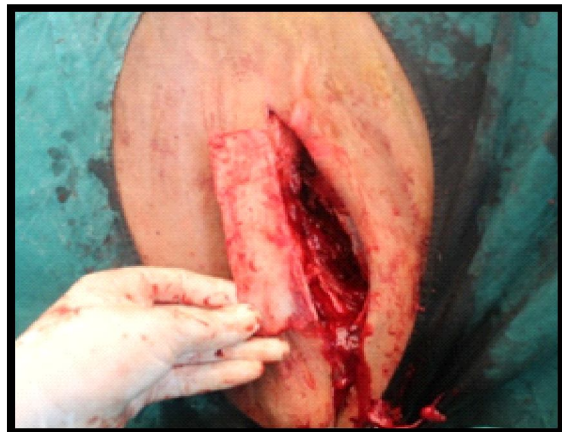

Fig 4: Complete removal of rib.

Ultrasound guided pericardiocentesis helped to confirm the nature of the pericardial fluid. The fluid colour was brownish with foul smelling (2 cases), reddish brown with bad smell (2 cases), straw color fluid without smell and yellow color with bad odour in one case each. Athar *et al.* (2012)

reported that pericardial fluid colour and smell vary according to the etiological agent involved and Misk (2015) opined that the pericardial fluid aspirates were yellowish, reddish, or whitish in colour with different viscosity according to the severity of the disease.

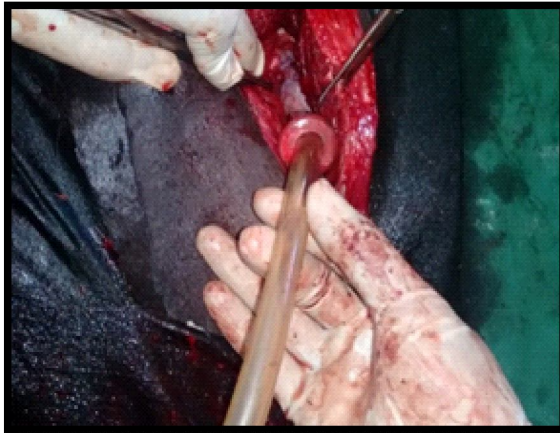

Fig 5: Draining of pericardial fluid from pericardial sac by suction pump.

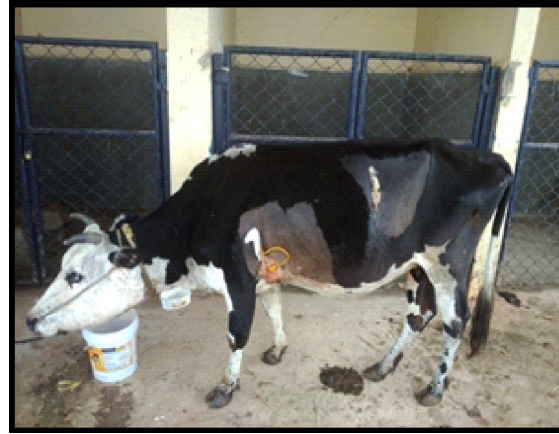

Fig 8: Post operative photographs.

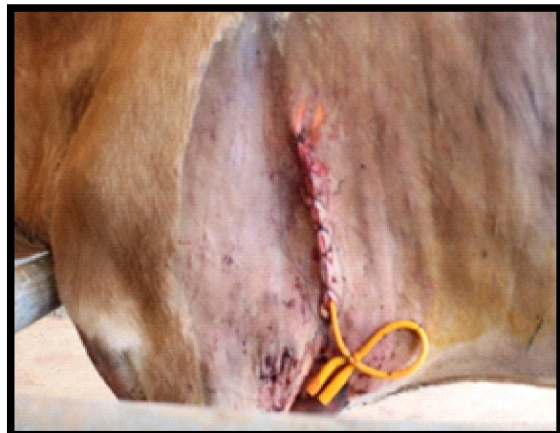

Fig 6: Closure of skin incision and fixing of Foley's catheter to skin.

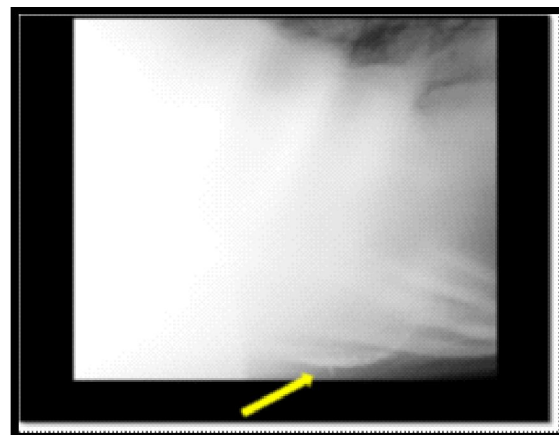


Fig 9: Lateral thoracic radiograph showing radioopaque sharp foreign body piercing the reticular wall.

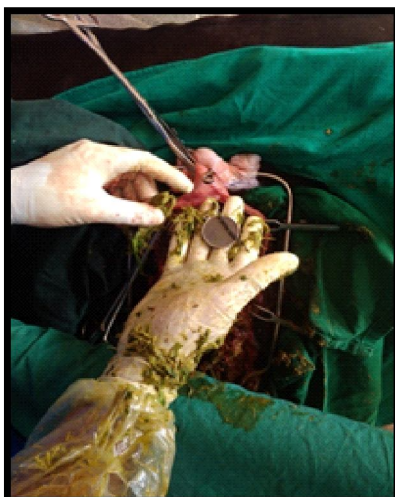

Fig 7: Foreign body removal through rumenotomy.

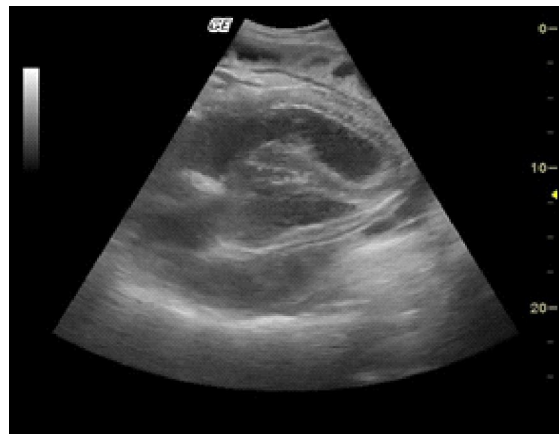


Fig 10: Ultrasound image showing hypoechoic areas with echogenic deposits suggestive of strands of fibrin interspersed between the pericardial sac.

Bacteriological isolation and culturing of pericardial fluid revealed presence of *E. coli* in two cases, *Staphylococcal*, *Clostridia*, *Pasteurella* and mixed infection in one case each.

Table 2: Mean±SE Haemato biochemical values of cattle affected with fibrinous pericarditis.

Parameters	Values	Reference value
Hb g%	7.783±0.480	8-15
PCV %	24.5±1.574	24-46
TEC (millions/μL)	5.35±0.239	5-10
Leukocyte count /μL	11±0.53	5-12
Lymphocytes (%)	57.5±1.335	45-75
Neutrophils (%)	44±1.335	15-45
Monocytes (%)	4.5±0.224	2-7
Eosinophils (%)	1.5±0.224	2-20
platelets (lakhs/μL)	3.12±0.294	2-8
ALT (IU/dL)	55.33±0.955	45-70
AST (IU/dL)	76±1.612	45-80
Glucose (mg/dl)	92.17±3.016	62-114
Plasma fibrinogen (g/ dl)	0.94±0.036	0.3-0.7
Total protein (g/dl)	7.78±0.135	6.7-7.5
Albumin (g/dl)	4.0±0.112	2.1-3.6
Globulin (g/dl)	3.78±0.13	2.0-3.9
A/G ratio	1.05±0.15	1.1-2.4
Sodium (mEq/mL)	134.21±0.23	130-140
Potassium (mEq/mL)	3.62±0.32	3.9-5.0
Chloride (mEq/mL)	103.13±0.53	95-110

Table 3: Ultrasonographic features in Fibrinous pericarditis.

Case no.	Breed	Ultrasonographic finding	Depth of pericardial space
1	Holstein friesian cross breed	Hyperechoic fibrinous strands attachment between epicardium and pericardium with anechoic fluid in between strand of fibrin	3.2 cm
2	Holstein Friesian cross breed	Hyperechoic fibrinous strands floating in the mixture of hyperechoic to echoic fluid in the pericardial space	3.1 cm
3	Holstein Friesian cross breed	Hypoechoic contents with hyperechoic strands floating in pericardial space	2.6 cm
4	Amruthmahal	Anechoic to echoic to fluid accumulation in the pericardial with hyper echoic fibrinous strands attached to heart	2.3 cm
5	Jersey cross breed	Mild anechoic fluids contain hyperechoic fibrin attachment to pericardial sac	4.1 cm
6	Jersey cross breed	Massive echoic fluids containing few streaks of hyperechoic fibrin strands floating in pericardial fluid	6.2 cm

Table 4: Pericardial fluid analysis and antibiogram.

Case no.	Breed	Color of pericardial fluids	Organism	Antibiotic sensitivity
1	Holstein friesian cross breed	Reddish to brown	Mixed infection	Ceftriaxone
2	Holstein friesian cross breed	Yellowish	Pasturella	Penicillin
3	Holstein friesian cross breed	Brownish	Clostridia	Ceftriaxone
4	Amruthmahal	Reddish brown	Ecoli	Ceftriaxone
5	Jersey cross breed	Brownish	Ecoli	Amoxicillin
6	Jersey cross breed	Straw	Staphylococcal	Penicillin

Antibiogram in present study suggested that the organisms were sensitive for Ciprofloxacin, Gentamicin, Penicillin, Amoxicillin, Streptomycin and Ceftriaxone (Table 4). Cytological examination of the pericardial fluid revealed presence of bacteria and degenerated neutrophils suggestive of infection and inflammation. Whereas Imran *et al.* (2011) reported gram negative bacilli in pericardial fluid, Manjunatha *et al.* (2018) reported presence of *E.coli*, *Staphylococcal* and bacteriological sterile cases in pericardial fluid of cattle. A mixed population of Gram's positive and Gram's negative aerobic and anaerobic organisms (gastrointestinal flora) sensitive to cephalixin, gentamicin, cotrimethoxazole, tetracycline and erythromycin as reported by Athar *et al.* (2012).

In the present study, pericardiotomy by 5th rib resection under local analgesia in standing position was performed as per procedure of Hendrickson (2007) which was found to be effective. Upon pericardiotomy 200 ml to 2000 ml of fluid was removed, hand was passed into pericardium for breaking of adhesions and examined for foreign bodies and Foleys catheter no-18 was placed in the pericardial cavity and fixed to skin. The foreign bodies like sewing needle and wire were removed from the reticulum by rumenotomy under left T₁₃, L₁ and L₂ paravertebral nerve block.

Postoperatively parental antibiotics were administered as per ABST reports like ceftriaxone sodium in three cases penicillin in two cases and amoxicillin in one case for seven days. Analgesic meloxicam was administered for three days. Supportive therapy like fluids, diuretics, B-complex supplements and anti-histamines was given for 5-7 days.

In total of six animals, one animal died on first surgical day, one died on fifth postoperative day, another two pregnant animals survived for 2 months and born to calf and alternative two animals survived for 6 months.

Proper placement of catheter in this study helped in proper drainage of pericardial or pleural accumulation in effective way. Braun (2009) opined that cattle almost have a poor prognosis and should be humanely euthanized as quick as possible and treatment should be attempted only in a valuable animal or in animal carrying high value embryo, whereas, in present study 5th rib resection followed by pericardiotomy yielded favorable result in animals suffering with fibrinous pericarditis. So early detection timely employment of suitable surgical technique can prolong the life of animal and can save the life of the young one.

CONCLUSION

Pericardiotomy is a reliable good technique in management of fibrinous pericarditis, this technique was helpful in breaking adhesions between epicardium and pericardium.

ACKNOWLEDGEMENT

Authors are thankful to the Honourable Vice Chancellor and Registrar of KVAFSU, Bidar and SVVU, Tirupathi for providing necessary facilities to complete present research study.

Conflict of Interest: None.

REFERENCES

- Abdelaal, A.M., Floeck, M., Maghawry, S.E. and Baumgartner, W. (2009). Clinical and ultrasonographic differences between cattle and buffaloes with various sequelae of traumatic reticuloperitonitis. *Veterinari Medicina*. 54: 399-406.
- Anteneh, M. and Ramaswamy, V. (2015). Hard ware disease in bovine (review article), *Academic Journal of Animal Diseases*. 3: 146-159.
- Ashwani Kumar, Narinder S. Saini, Jitender Mohindroo and Naresh K. Sood. (2012). Ultrasonographic features of normal heart and liver in relation to diagnose pericarditis in bovine. *Indian Journal of Animal Sciences*. 12: 1489-1494.
- Athar, H., Parrah, J.D., Moulvi, B.A., Singh M. and Dedmari, F.H. (2012). Pericarditis in Bovines- A Review. *International Journal of Advanced Veterinary Science and Technology*. 1: 19-27.
- Attia, N.E. (2016). Cardiac biomarkers and ultrasonography as tools in prediction and diagnosis of traumatic pericarditis in Egyptian buffaloes. *Veterinary World*. 9(9): 976-982.
- Braun, U. (2009). Traumatic pericarditis in cattle: Clinical, radiographic and ultrasonographic findings. *Veterinary Journal*. 182: 176-186.
- Braun, U., Schweizer, T. and Pusterla, N. (2001). Echocardiography of the normal bovine heart: Technique and ultrasonographic appearance. *Veterinary Record*. 148: 47-51.
- Braun, U., Lejeune, B., Schweizer, G., Puorger, M. and Ehrensperger, F. (2007). Clinical findings in 28 cattle with traumatic Pericarditis. *Veterinary Record*. 161: 558-563.
- Buczinski, S., Francoz, D., Fecteau, G. and Di Frusica, R. (2010). Heart diseases in cattle with clinical signs of heart failure: 59 cattle. *Canadian Veterinary Journal*. 51: 1123-1129.
- Dehghani, S.N. and Molaei, M.M. (1999). Pericardiotomy Vs intermittent pericardial lavage for treatment of pericarditis in cattle: An experimental study. *Indian Journal of Veterinary Surgery*. 20: 22-24.
- Gavali, M.B., Aher, V.D. and Bhikane, A.U. (2003). Surgical management of traumatic pericarditis in bovine - A clinical study. *Indian Veterinary Journal*. 80: 556-559.
- Hendrickson, D.A. (2007). Rib Resection and Pericardiotomy. In: *Techniques of Large Animal Surgery*. (3rd Edn.) Lea and Febiger, USA. 282-286.
- Hussein, H.A. and Staufenbiel, R. (2014). Clinical presentation and ultrasonographic findings in buffaloes with congestive heart failure. *Turkish Journal of Veterinary and Animal Science*. 38: 534-545.
- Ibrahim, H.M.M. and Gomaa, N.A. (2016). Traumatic pericarditis in cattle: Risk factors clinical features and ultrasonographic findings. *Journal of Veterinary Science and Medical Diagnosis*. 3: 1-6.
- Imran, S., Tyagi, S.P. and Sharma, S. (2011). Ultrasonographic application in the diagnosis and prognosis of pericarditis in cows. *Veterinary Medicine International*. 10: 1-10.
- Jain, N.S., (1986). Haematological Techniques. In: *Schalm's Veterinary Haematology*. 4th edn., Lea and Febiger, Philadelphia. pp. 20-86.
- Khalphallah, A., Hanan, K., Abedellaah Doaa, Salman Al-Iethie, A. Al-Iethie and Sara Bayoumi, A. (2017). Ultrasonography as a diagnostic tool in Egyptian buffaloes with traumatic pericarditis. *International Journal of Veterinary Science and Medicine*. 2: 159-167.
- Manjunatha, D.R., Nagaraju, N., Basavarju, B.B., Suresh, L., Dilipkumar, D., Shivaprakash, B.V. and Vasanth, M.S. (2018). Traumatic pericarditis in bovines: Its diagnosis and surgical management. *Journal of Veterinary Surgery*. 2: 96-99.
- Misk, N.A. (2015). Thoracocentesis for diagnosis of traumatic pericarditis and diaphragmatic hernia in cattle and buffaloes. *Assiut Veterinary Medicine Journal*. 145: 70-74.
- Premkumar, C., Dharmaceelan, S., Rajendran, N. and Jagadeeswaran, A. (2019). Ultrasound diagnosis and pericardiocentesis under local analgesia for traumatic pericarditis in cattle - A clinical study. *The Pharma Innovation Journal*. 3: 92-96.
- Radostits, O.M., Gray, C.C., Hinchcliff, K.W. and Constable, P.D. (2007). *Veterinary Medicine A Textbook of the Diseases of Cattle, Horses, Sheep, Pigs and Goats*. (10th Edn.). Saunders Elsevier, Philadelphia. pp. 430-32.
- Sasikala, K., Vijayakumar, G., Sivaraman, S. and Balasubramaniam, G.A. (2018). Clinicodiagnostic studies on traumatic reticulopericarditis in cattle - A review of 56 cases. *International Journal of Current Microbiology and Applied Sciences*. 5: 513-523.
- Tharwat, (2011). Traumatic Pericarditis in Cattle: Sonographic, Echocardiographic and Pathologic Findings. *Journal of Agricultural and Veterinary Sciences Qassim University*. 1: 45-59.
- Tranquilli, W.J., Thurmon, J.C. and Grimm, K.A. (2007). *Lumb and Jones' Veterinary Anesthesia and Analgesia*. (4th edn.). Blackwell Publishers, pp. 731-743.