B-5727
[1-9]

RESEARCH ARTICLE Indian Journal of Animal Research

Pathological, Molecular and Lesion Scoring Studies of Ocular Marek's Disease in Commercial Layer Chickens

R. Ravikumar[1], J. Selvaraj[2], T. Lurthu Reetha[3],
S. Balakrishnan[4], R. Thangathurai[5], D. Basheer Ahamad[1]

10.18805/IJAR.B-5727

ABSTRACT

Background: Marek's disease (MD) has re-emerged as a significant threat to Indian poultry despite widespread vaccination, causing annual losses of 40 million Indian rupees with 10-40% mortality in vaccinated flocks across Punjab, Assam, Uttar Pradesh and Andhra Pradesh. The emergence of virulent (vMDV) and very virulent (vvMDV) pathotypes challenges disease management. Indian field isolates are categorized into mild, virulent, very virulent and very virulent plus pathotypes based on serotype 1-specific gene sequencing, with virulence correlating to fewer PPPP (four prolines) repeat sequences in the Meq gene.

Methods: This study investigated 46 MD suspected eye cases from 25 commercial layer farms in Namakkal and Thalaivasal districts, Tamil Nadu. Ocular manifestations predominantly affected birds aged 36-64 weeks, presenting with swollen closed eyes, conjunctivitis and greyish-white iris discoloration. Histopathological (HP) examination revealed 18 positive cases (39.13%), confirmed by PCR.

Result: A modified scoring system (0-5) assessed pleomorphic lymphoid cell infiltration severity: Score 1 showed multifocal mild perivascular infiltration in choroid; Score 2 demonstrated focal moderate choroidal/iris infiltration; Score 3 revealed severe choroidal infiltration with lens fibre vacuolation; Score 4 showed diffuse moderate iris infiltration with mixed inflammatory cells; Score 5 exhibited diffuse severe iris and choroidal infiltration.Enhanced surveillance, improved biosecurity and more effective vaccines against virulent strains are essential for controlling this re-emerging disease in Indian poultry.

Key words: Eye, Polymerase chain reaction, Histopathology, Layer chicken, Lesion score, Marek's disease, Pleomorphic lymphoid Cell (PLC).

INTRODUCTION

Marek's disease (MD) is a highly contagious oncogenic and neuropathic disease of chickens caused by an alphaherpesvirus that spreads through the environment via feather follicles and infects birds through inhalation, resulting in substantial economic losses to the global poultry industry (Morrow and Fehler, 2004). First recognized by Dr. József Marek in 1907 as paralysis of roosters, MD almost devastated the poultry industry in the 1960s before being brought under control following the development of live vaccines using Herpes Virus of Turkey (HVT) in the 1970s. However, variant MD viruses with increased pathogenicity subsequently evolved, necessitating the development of new vaccines to combat these more virulent strains (Kannaki and Gowthaman, 2020).

The causative agent, Marek's disease virus (MDV), belongs to the order Herpesvirales, family Herpesviridae, subfamily Alphaherpesvirinae and genus Mardivirus (ICTV, 2011; Davison, 2010). This cell-associated herpes virus consists of linear, double-stranded DNA of 160-180 kbp in size (Balena *et al.,* 2019; Suresh *et al.,* 2020) and is classified into three serotypes based on biological properties (Witter and Schat, 2003). Serotype 1 MDV is virulent and oncogenic, while serotypes 2 and 3 (HVT) are non-pathogenic vaccine strains. Serotype 1 strains are further categorized into pathotypes based on their ability to

[1]Department of Veterinary Pathology, Veterinary College and Research Institute, Tamil Nadu Veterinary and Animal Sciences University, Theni-625 534, Tamil Nadu, India.
[2]Department of Veterinary Pathology, Veterinary College and Research Institute, Tamil Nadu Veterinary and Animal Sciences University, Orathanadu-614 625, Tamil Nadu, India.
[3]Department of Veterinary Microbiology, Veterinary College and Research Institute, Tamil Nadu Veterinary and Animal Sciences University, Orathanadu-614 625, Tamil Nadu, India.
[4]Department of Veterinary Public Health and Epidemiology, Veterinary College and Research Institute, Tamil Nadu Veterinary and Animal Sciences University, Orathanadu-614 625, Tamil Nadu, India.
[5]Department of Veterinary Pathology, Veterinary College and Research Institute, Tamil Nadu Veterinary and Animal Sciences University, Tirunelveli-627 001, Tamil Nadu, India.

Corresponding Author: R. Ravikumar, Department of Veterinary Pathology, Veterinary College and Research Institute, Tamil Nadu Veterinary and Animal Sciences University, Theni-625 534, Tamil Nadu. India. Email: ravikumar1975path@gmail.com

How to cite this article: Ravikumar, R., Selvaraj, J., Reetha, T.L., Balakrishnan, S., Thangathurai, R. and Ahamad, D.B. (2026). Pathological, Molecular and Lesion Scoring Studies of Ocular Marek's Disease in Commercial Layer Chickens. *Indian Journal of Animal Research.* 1-9. doi: 10.18805/IJAR.B-5727.

Submitted: 28-11-2025 **Accepted:** 18-02-2026 **Online:** 02-03-2026

induce lymphoproliferative lesions and disease severity in vaccinated chickens (Witter *et al.,* 2005).

MD is characterized by the development of CD4+ T-cell lymphomas and infiltration of nerves and visceral organs by lymphocytes. The virus replicates directly in the bursa of Fabricius and thymus, severely compromising both humoral and cell-mediated immunity (Ravikumar *et al.,* 2024). Clinical manifestations include mononuclear cell infiltration in peripheral nerves, gonads, lymphoid organs, iris, muscle, comb, skin and other visceral organs, resulting in tumor development, paralysis of extremities and neck, grey eye or irregular pupil, vision impairment, blindness, skin lesions and immunosuppression (Akhila *et al.,* 2022).

Despite widespread vaccination programs, sporadic MD outbreaks continue to be reported globally in vaccinated flocks (Okwor *et al.,* 2011), including in India (Arulmozhi *et al.,* 2011; Gopal *et al.,* 2012), where the disease has re-emerged as a significant threat. The emergence of virulent (vMDV) and very virulent (vvMDV) pathotypes represents a critical challenge in disease management (Dunn and Gimeno, 2013), with annual economic losses in India alone estimated at approximately 40 million rupees (Sudhakar and Nair, 2013). Commercial poultry farming's intensive systems provide conducive environments for the emergence of new pathogens and re-emergence of previously controlled pathogens with enhanced virulence, leading to evolved strains that can overcome vaccinal immunity and cause atypical MD presentations (Ravikumar *et al.,* 2025).

Modern MD presentations often include tumour lesions in skin, comb and eyes in addition to classical visceral organ involvement. Eye lesions, in particular, serve as readily observable external indicators of MD infection, making them valuable for early detection and diagnosis in commercial flocks. These ocular manifestations predominantly affect birds aged 36-64 weeks and present with characteristic clinical signs including swollen closed eyes, conjunctivitis and greyish-white iris discoloration.

Despite the diagnostic significance of eye lesions in MD, there remains limited systematic documentationof their gross and histopathological characteristics with standardized scoring systems. Such documentation is crucial for improving diagnostic accuracy and disease surveillance in commercial poultry operations. The development of a reliable histopathological scoring system based on pleomorphic lymphoid cell infiltration patterns would enhance diagnostic consistency and facilitate better understanding of disease progression in ocular tissues. Therefore, this study aims to describe the gross and histopathological features of eye lesions in MD-affected commercial layer chickens from Tamil Nadu, India and develop a standardized lesion scoring system for enhanced diagnostic reliability. By establishing clear criteria for ocular MD lesion assessment, this research contributes to improved surveillance and control strategies for this economically important re-emerging disease in vaccinated poultry flocks.

MATERIALS AND METHODS

The research work on"Pathological, Molecular and Lesion Scoring Studies of Ocular Marek's Disease in Commercial Layer Chickens" was carried out in the Department of Veterinary Pathology, Veterinary College and Research Institute, Orathanadu of Tamil Nadu Veterinary and Animal Sciences University, Tamil Nadu during the period between October 2016 and March 2019.

A total of 46 Marek's disease (MD) suspected eye cases from 25 commercial layer chicken farms were studied in and around Namakkal District and Thalaivasal (Salem District), Tamil Nadu, India. Affected chickens showed closed eyes (Fig 1), swollen eyelids (Fig 2), conjunctivitis and greyish-white iris discoloration (Fig 3 and Fig 4). A detailed necropsy of all birds was carried out and the gross lesions of eyes were photographed. Conjunctivitis and greyish-white iris discoloration lesions in the MD suspected eye were chosen for site of tissue sampling for HP examination. A transverse section of tissue with approximately 5 mm thickness was taken from the eye suspected for MD.

The eye tissue samples were fixed in 10% neutral buffered formalin and a routine histological technique was performed. Briefly, tissues were dehydrated in ascending grades of alcohol, cleared in xylene (2 changes) and embedded in paraffin. Sections were cut with a thickness of 5-µm and stained with hematoxylin and eosin and mounted with Distyrene plasticizer xylene (DPX) for HP examinations (Suvarna *et al.,* 2013).

A histopathological lesion scoring system was employed (0-5), based on the amount of lymphoid infiltration in the eye and the tissue distribution it had in the eye (Ravikumar *et al.,* 2025). The criteria for scoring were modified from established protocols (Table 1).

Total scores for MD affected eye are sum of all the scores multiplied with its respective cases affected. Mean scores are obtained by dividing total scores with total cases examined.

Suspected eye tissue samples were collected in dry ice for PCR confirmation. DNA was extracted by DNeasy blood and tissue kit as per manufacture' instruction(M/s Qiagen, Germany). The obtained DNA was stored at -20°C until for further analysis (Pazhanivel *et al.,* 2023). Then,polymerasechain reaction was carried out by using previously reported primer set forMD as shown in Table 2.

The PCR reactions was carried out in final volume of 25 µl which include volume of 12.5 µl of master mix (2 X), 1 µl of forward and reverse primer each (10 pmol/µl), 7.5 µl of deionized water and 3 µl of extracted DNA and the above mixture of materials was subjected to PCR in a thermal cycler (Eppend orff) as per the procedure of Gong *et al.* (2013). The analysis of PCR product was carried out in 1.5 per cent agarose gel stained with ethidium bromide (0.5 µg/ml) and documented under gel documentation system (Ravikumar *et al.,* 2019).

Fig 1: MD- Chicken - Dull, depressed and closed eyes.

Fig 2: MD- Chicken - Closed eyes and swelling of eyelids.

Fig 3: MD- Chicken - Irish -Greyishwhite discoloration.

Fig 4: MD- Chicken - Iris -Greyishwhite discoloration.

Table 1: Histopathological lesion score for LPDs.

Score	Lesions	Pictograph	Number of cellsinvolved (approximately)
0	Tissue architecture is normal. No lymphoid cell infiltration		0
1	Focal mild orMultifocal mild cell infiltration	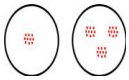	10 (5-15)
2	Focal moderate or Diffuse mild cell infiltration	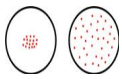	17 (10-25)
3	Focal severe or Multifocal moderate or Confluent moderate cell infiltration	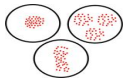	30 (20-40)
4	Multifocal severe or Diffuse moderate or Confluent severe cell infiltration	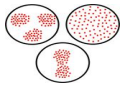	65 (50-80)
5	Diffuse severe cell infiltration		100

RESULTS AND DISCUSSION

The present study examined 46 eyes from MD suspected commercial layer chickens, with the affected age groups ranging from 36 to 64 weeks of age. Following detailed HP examination, 18 samples (39.13 per cent) were confirmed positive for MD, while 28 samples (60.87 per cent) showed no lesions and were scored as 0. Among the 18 positive cases, the distribution of lesion scores revealed varying degrees of severity: score 1 was observed in 4 cases (8.70 per cent), score 2 in 2 cases (4.35 per cent), score 3 in 6 cases

Table 2: Primer used for detection of MD viruses.

Virus	Primer	Sequence	Gene and size	Reference
MDV	Forward	F 5 -GGC ACG GTA CAG GTG TAA AGA G-3		
	Reverse	R 5 -GCA TAG ACG ATG TGC YGC TGA G-3	*Meq*,1081 bp	Gong *et al.* (2013)

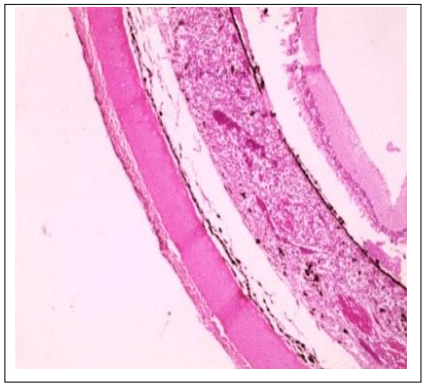

Fig 5: MD-Eye - Score 1- Choroid showing mild PLC infiltration -H and EX 40.

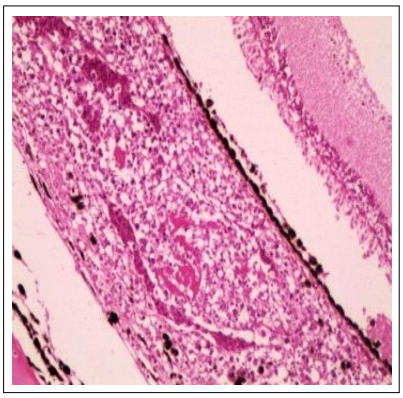

Fig 6: MD-Eye - Score 1- Choroid layer showing focal mild PLC infiltration -H and EX 100.

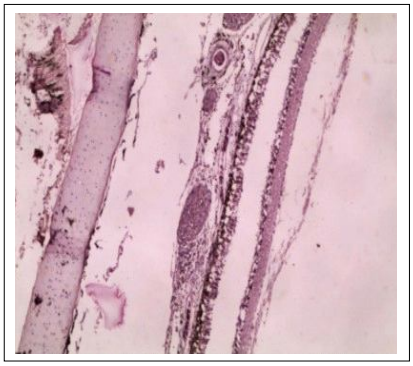

Fig 7: MD-Eye - Score 1- Choroid layer showing focal mild PLC infiltration -H and EX 40.

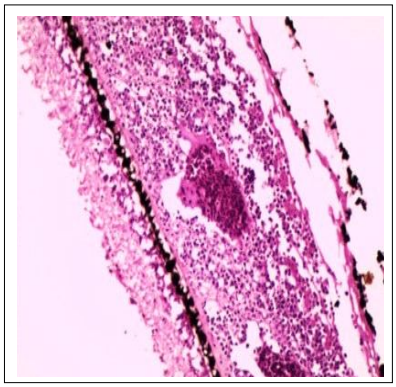

Fig 8: MD-Eye - Score 2- Choroid showing moderate PLC infiltration -H and EX 100.

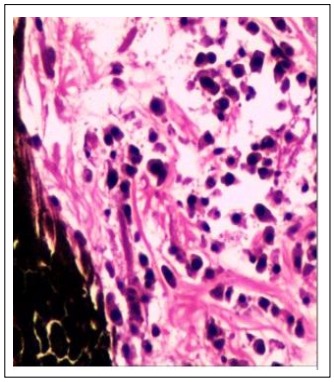

Fig 9: MD-Eye - Score 2- Iris showing focal PLC infiltration -H and EX 400.

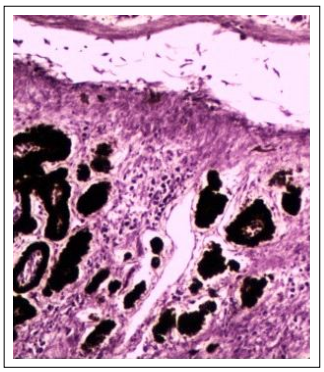

Fig 10: MD-Eye - Score 2- Ciliary body showing diffuse mild PLC infiltration-H and EX 100.

(13.04 per cent), score 4 in 4 cases (8.70 per cent) and score 5 in 2 cases (4.35 per cent). The total lesion score for all eye samples was calculated as 52, derived from the formula:

$$(4\times1) + (2\times2) + (6\times3) + (4\times4) + (2\times5) = 52$$

The mean lesion score was determined by dividing the total score by the total number of cases examined (52/46), yielding a value of 1.13. This relatively low mean score indicates that while MD ocular lesions were present in a significant proportion of suspected cases, the majority of examined eyes either showed no lesions or demonstrated mild to moderate pathological changes.

HP examination of MD positive eye samples revealed progressive patterns of pleomorphic lymphoid cell (PLC) infiltration across different ocular structures. Eyes classified as Score-1 (4 cases) demonstrated multifocal mild perivascular PLC infiltration specifically localized to the choroid layer (Fig 5, 6 and Fig 7) representing the earliest detectable histopathological changes. Score-2 lesions (2 cases) exhibited focal moderate PLC infiltration in both the choroid (Fig 8) and iris accompanied by diffuse mild PLC infiltration extending to the iris (Fig 9), ciliary body (Fig 10) and choroid layer, indicating disease progression with broader tissue involvement. Score-3

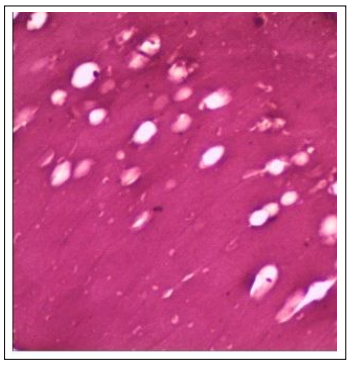

Fig 11: MD- Eye - Score 3- Lens showing subcortical vacuolation of lens fibre -H and EX 100.

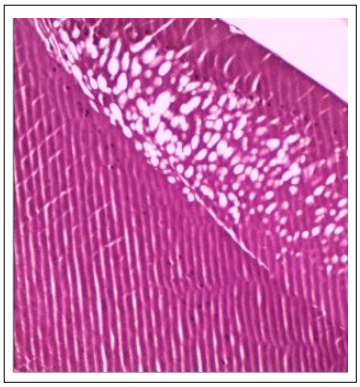

Fig 12: MD- Eye - Score 3- Lens showing subcortical vacuolation of lens fibre -H and EX 100.

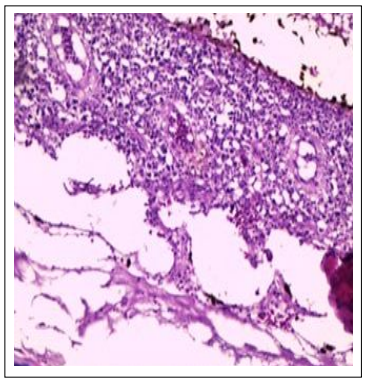

Fig 13: MD- Eye - Score 3- Choroid showing patchy moderate PLC infiltration -H and EX 100.

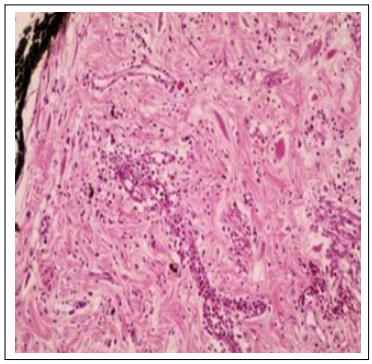

Fig 14: MD - Eye -Score 4- Iris showing diffuse moderate PLC infiltration -H and EX 100.

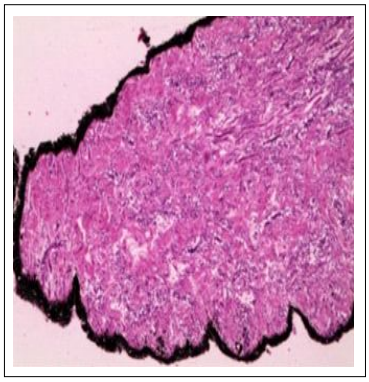

Fig 15: MD -Eye - Score 4- Iris showing diffuse moderate PLC infiltration -H and EX 100.

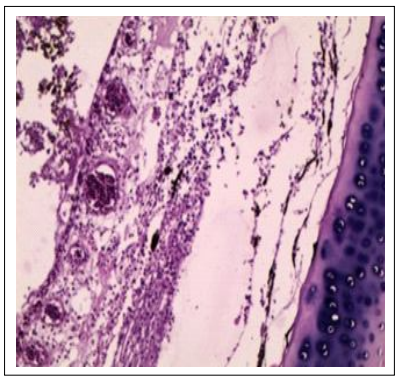

Fig 16: MD -Eye - Score 4- Choroid showing diffuse moderate PLC infiltration -H and EX 40.

lesions (6 cases), which constituted the largest proportion of positive cases, showed focal severe PLC infiltration in the choroid layer along with additional pathological features including subcortical vacuolation of lens fibres (Fig 11 and Fig 12) and patchy moderate PLC infiltration in the choroid (Fig 13), suggesting more advanced disease with multiple tissue compartments affected. Score-4 lesions (4 cases) were characterized by diffuse moderate PLC infiltration in the iris (Fig 14 and Fig 15) and choroid (Fig 16) accompanied by a mixed inflammatory cell population consisting of lymphocytes, macrophages and plasma cells, reflecting a more extensive immune response. The most severe lesions, classified as Score-5 (2 cases), demonstrated diffuse severe PLC infiltration affecting both the iris (Fig 17), choroid layers (Fig 18) and corneo-paplpebral conjunctival junction (Fig 19). Besides choroid showed congestion (Fig 20) and cornea showed oedema with epithelium proliferation (Fig 21 and Fig 22) representing the most advanced stage of ocular MD pathology observed in this study. Polymerase chain reaction (PCR) analysis confirmed MD in all 18 histopathologically positive cases (39.13% positivity rate), demonstrating perfect concordance

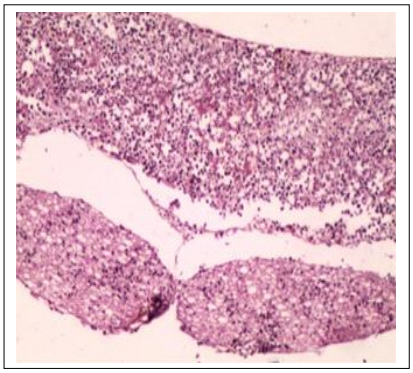

Fig 17: MD - Eye - Score 5- Choroid showing diffuse severe PLC infiltration -H and EX 100.

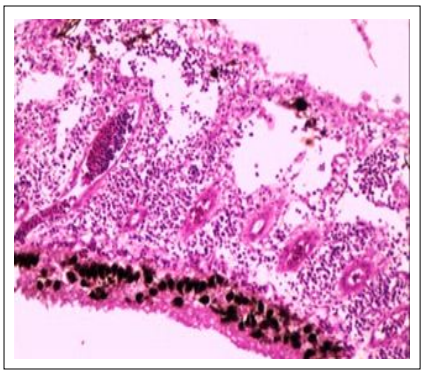

Fig 20: MD- Eye- Score 5-Choroid- Congestion and PLC infiltration -H and EX 100.

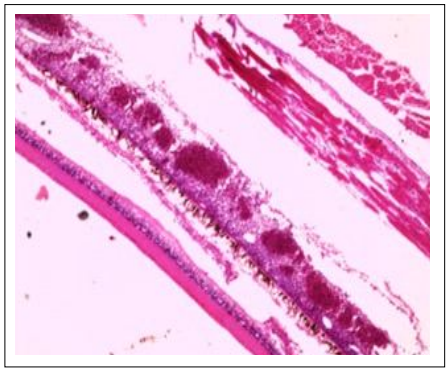

Fig 18: MD - Eye - Score 5- Choroid showing diffuse severe PLC infiltration -H and EX 40.

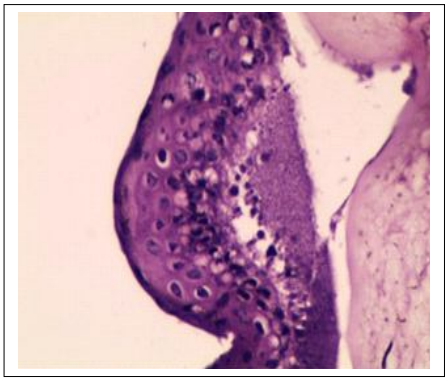

Fig 21: MD - Eye- Score 5-Cornea oedema -H and EX 400.

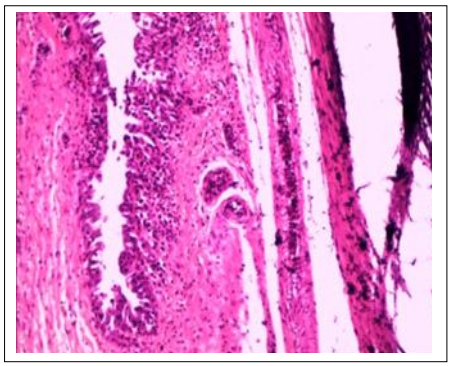

Fig 19: MD -Eye- Score 5-Corneo-paplpebral conjunctival junction - PLC infiltration -H and EX 100.

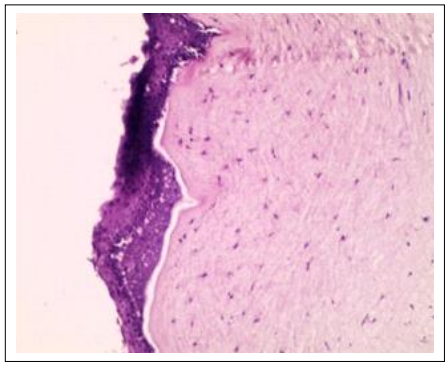

Fig 22: MD-Eye - Score 5- Cornea oedema with epithelium proliferation -H and EX 100.

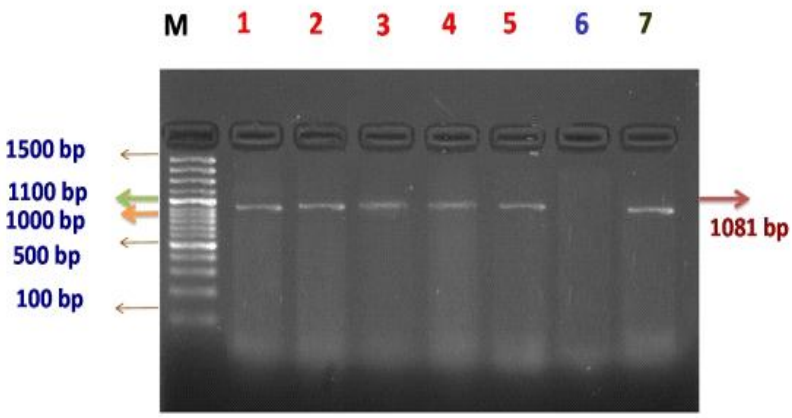

M-100 bp ladder, 1, 2,3,4,and 5 positive saples with a band at 108 bp specific for MD,6-Negative control and 7-Positive control

Fig 23: MDV-*Meq*gene-1081 bp PCR product on agarose gel electrophoresis.

between histopathological and molecular diagnostic methods.

The PCR amplification of the *Meq* gene of MDV (Shailija *et al.,* 2023) was successfully demonstrated by agarose gel electrophoresis (Fig 23), providing definitive molecular confirmation of the histopathological diagnosis and validating the reliability of the lesion scoring system employed in this investigation (Ravikumar *et al.,* 2023).

The age-wise incidence of MD recorded in this study ranged from 36 to 64 weeks, which is in agreement with previous observations (Ravikumar *et al.,* 2025). The PCR confirmation rate of 39.13% (18 out of 46 suspected cases) demonstrates the importance of molecular validation in MD diagnosis, as clinical suspicion alone may not always correlate with actual infection status. This finding emphasizes the necessity of combining gross pathological examination with molecular diagnostic techniques for accurate disease confirmation.

The gross pathological findings revealed that in most cases, eyes showed conjunctivitis. In fewer cases, the iris showed greyish-white discoloration. These results are consistent with earlier reports (Mete *et al.,* 2016). In MD affected birds, bulged eyeball with cloudy iris and irregular narrow pupil were observed, which corroborate the findings of (Muniyellappa *et al.* 2013). Heidari *et al.* (2016) observed that the eyelids were stretched and overextended. Mete *et al.* (2016) reported grey discoloration of the iris circumferentially around the pupil, diffuse iris reddening, anisocoria (unequal pupil size) and dyscoria (abnormal pupil shape) in the eyes of 2-month to 3-year-old backyard chickens, which align with the clinical presentations observed in the current study.

In the present study, histopathological examination revealed that the choroid layer was affected initially with multifocal mild perivascular pleomorphic lymphoid cell (PLC) infiltration (Score 1), representing the earliest detectable ocular lesions. As the lesions progressed (Score 2), iris and ciliary body were also involved, demonstrating the sequential spread of pathological changes. In Score 3 cases, focal severe PLC infiltration was observed in the choroid with subcortical vacuolation of lens fibers and the palpebral conjunctiva showed multifocal moderate PLC infiltration. These findings are consistent with earlier workers (Fujimoto *et al.*, 1971; Pandiri *et al.,* 2008), who documented similar progressive patterns of ocular involvement. Pandiri *et al.* (2008) noted that ocular lesions started very early after infection and progressed in severity and distribution with time, which supports the scoring system employed in the current study. However, severe congestion, hemorrhages and pale eosinophilic material between different layers were also noticed by Ali *et al.* (2014), whereas retinal pigmented epithelial necrosis and separation, plaques and fibrovascular membrane formation in the anterior iris were observed by Mete *et al.* (2016), indicating that MD ocular pathology can manifest with varying degrees of severity and tissue-specific complications.

The progressive nature of ocular lesions observed in the present study, from initial mild perivascular infiltration in the choroid (Score 1) to severe diffuse infiltration affecting multiple ocular structures (Score 5), demonstrates a clear pattern of disease progression. This scoring system provides a standardized approach for evaluating MD ocular pathology and may serve as a valuable tool for disease surveillance and monitoring in commercial poultry operations. The perfect concordance between histopathological findings and PCR confirmation validates the reliability of histopathological diagnosis when applied systematically. However, the molecular confirmation remains essential for definitive diagnosis, particularly in early or atypical cases where histopathological changes may be subtle or ambiguous.

CONCLUSION

In the present study, MD was successfully diagnosed through combined pathological and molecular approaches using PCR in layer chickens aged 36 to 64 weeks, with a

39.13% confirmation rate demonstrating the critical gap between clinical suspicion and laboratory-confirmed diagnosis. The emergence of highly pathogenic MDV isolates capable of overcoming vaccine protection has led to atypical presentations including ocular lesions, posing significant challenges to poultry health management and underscoring the evolving nature of this disease. The developed standardized histopathological scoring system (0-5) for eye lesions, based on the severity and distribution of pleomorphic lymphoid cell infiltration, provides a valuable diagnostic tool for field veterinarians and researchers, enabling consistent evaluation of disease severity and progression in commercial flocks.

MD continues to threaten poultry welfare and economic viability through increased carcass condemnation, reduced productivity and substantial economic losses, while its immunosuppressive effects increase susceptibility to secondary infections, further compounding production losses. The findings of this study emphasize the importance of integrating clinical observation, gross pathology, histopathological examination and molecular diagnostics for accurate MD diagnosis. A successful MD prevention and control program requires a multifaceted approach including early vaccination of day-old chicks with appropriate vaccine strains, timely booster doses when necessary, implementation of stringent biosecurity measures to minimize virus exposure, regular disease surveillance and continuous monitoring for vaccine breakthrough cases. Enhanced awareness of ocular manifestations as early indicators of MD infection can facilitate timely intervention and improved disease control in commercial poultry operations, ultimately contributing to better flock health and economic sustainability of the poultry industry.

Conflict of interest

All authors declared that there is no conflict of interest.

REFERENCES

Akhila, N., Samatha, V., Rama Devi, V., Sudha Rani Chowdary, Ch., Yashaswi, Y. and Padmini, V. (2022). Pathological and molecular diagnosis of Marek's disease in desi birds. *The Pharma Innovation Journal*. **SP-11(7):** 3995-3999.

Ali, A.M.A., El-Sayed, R.A., El-Attar, MH., Mohamed. and Ghany, H. M.A. (2014). Comparative diagnostic studies on Marek's disease in chickens by use of histopathology and molecular investigation. *Zag. Vet. J.* **42(3):** 225-241.

Arulmozhi, A., Kumanan, K., Raman, M. and Gopalakrishnamurthy, T.R. (2011). Marek's disease in vaccinated chicken flocks in Tamil Nadu, India. *Tropical Animal Health and Production*. **43(7):** 1397-1400.

Balena, V.R., Reddy, M.R., Singh, R., Asok Kumar, M., Palanivelu, M., Karikalan, M., Parthasarathi, B.C. and Snehil, G. (2019). Identification of very virulent Marek's disease virus strains in India by sequence analysis of 132 bbp repeats of *Bam H-HI* region. *Indian Journal of Animal Research.* **53(10):** 1382-1385. doi: 10.18805/ijar.B-3652.

Davison, A.J. (2010). Herpesvirus systematics. *Veterinary Microbiology*. **143(1):** 52-69.

Dunn, J.R. and Gimeno, I.M. (2013). Current status of Marek's disease in the United States and worldwide based on a questionnaire survey. *Avian Diseases*. **57(2):** 483-490.

Fujimoto, Y., Nakagawa, M., Okada, K., Okada, M.and Matsukawa, K. (1971). Pathological studies of Marek's disease: The histopathology on field cases in Japan. *Jpn. J. Vet. Res.* **19:** 7-26.

Gong, Z., Zhang, L., Wang, J., Chen, L., Shan, H., Wang, Z. and Ma, H. (2013). Isolation and analysis of a very virulent Marek's disease virus strain in China. *Virol. J.* **10:** 155-162.

Gopal, T., Suryanarayana, V.V.S., Srinivas, J. and Patnaikuni, R.K. (2012). Occurrence of Marek's disease in vaccinated commercial layer flocks of Andhra Pradesh. *Indian Journal of Animal Sciences*. **82(6):** 615-618.

Heidari, M., Wang, D., Fitzgerald, S.D. and Sun, S. (2016). Severe necrotic dermatitis in the combs of line 63 chickens infected with Marek's disease virus. *Avian Pathology*. **45:** 582-592.

ICTV. (2011). Virus Taxonomy: Classification and Nomenclature of Viruses: Ninth Report of the International Committee on Taxonomy of Viruses. Academic Press.

Kannaki, T.R. and Gowthaman, V. (2020). Marek's disease: Time to review the emerging threat in Indian poultry. *World's Poultry Science Journal*. **76(1):** 91-99.

Mete, A., Gharpure, R., Pitesky, M.E., Famini, D., Sverlow, K. and Dunn, J. (2016). Marek's disease in backyard chickens, a study of pathologic findings and viral loads in tumourous and non tumourous birds. *Avian Dis.* **60:** 826-836.

Morrow, C. and Fehler, F. (2004). Marek's disease: A Worldwide Problem. In *Marek's Disease* Elsevier. (pp. 49-61).

Muniyellappa, H.K., Satyanarayana, M.L., Isloor, S. and Gowda, N.K.S. (2013). Marek's disease outbreak among vaccinated commercial layer flocks in the mining area of Karnataka. *Vet. Rec.* **172:** 452-453.

Okwor, E.C., Eze, D.C., Okonkwo, I.O., Shoyinka, S.V.O. and Chah, K.F. (2011). Outbreak of Marek's disease in vaccinated pullet flock. *International Journal of Poultry Science*. **10(4):** 283-286.

Pandiri, A.K.R., Cortes, A.A.L., Lee, A.L.F. and Gimeno, I.M. (2008). Marek's disease virus infection in the eye: Chronological study of the lesions, virus replication and vaccine-induced protection. *Avian Dis.* **52:** 572-580.

Pazhanivel, N., Divya, M., Parthipan, M., Dhinakar Raj, G., John Kirubaharan, J., Sathish,G. and Manjari, K. (2023). Molecular method of Marek's disease virus serotype 2 detection using Polymerase chain reaction in chicken. *Indian J. Anim. Res.* 1-5. doi: 10.18805/IJAR.B-5079.

Ravikumar, R., Selvaraj, J., Balasubramaniam, G.A., Balakrishnan, S., LurthuReetha, T. and Thangathurai, R. (2019). Occurrence of Marek's disease in commercial layer chicken. *Int. J. Curr. Microbiol. App. Sci.* **8(9):** 2422-2426.

Ravikumar, R., Selvaraj, J., Balasubramaniam, G.A., Balakrishnan, S., LurthuReetha, T. and Thangathurai, R. (2023). Gross and histopathological studies of co-infection of Marek's disease and lymphoid leucosis in commercial layer chicken. *The Pharma Innovation Journal*. SP-**12(10):** 2069-2071.

Ravikumar, R., Selvaraj, J., LurthuReetha, T., Balakrishnan, S., Thangathurai, R. and Basheer Ahamad, D. (2024). Occurrence of lymphoproliferative diseases in commercial layer chicken. *International Journal of Veterinary Sciences and Animal Husbandry*. **SP-9(4):** 88-91.

Ravikumar, R., Selvaraj, J., LurthuReetha, T., Balakrishnan, S., Thangathurai, R. and Basheer Ahamad, D. (2025). Histopathological characterization and lesion scoring system for Marek's disease -associated comb lesions in commercial layer chickens. *AMA, Agricultural Mechanization in Asia, Africa and Latin America*. **56(09):** 21371-21381.

Ravikumar, R., Selvaraj, J., Lurthu Reetha, T., Balakrishnan, S., Thangathurai, R. and Basheer Ahamad, D. (2025). Histopathological lesions of brain and bone marrow of lymphoproliferative diseases in commercial layer chicken. *International Journal of Veterinary Sciences and Animal Husbandry*. **10(10):** 23-28.

Shailija, P., Deepika, L., Aman, K., Vikas, N., Babu, L.J. and Gulsan, N. (2023). Molecuar and Immunopathological investigations of Marek's disease in HVT vaccinated Chicken flocks. *Indian Journal of Animal Research.* doi: 10.18805/IJAR.B-5064.

Sudhakar, K. and Nair, G. (2013). Marek's disease virus in Indian poultry: A review. *Indian Journal of Comparative Microbiology, Immunology and Infectious Diseases*. **34(1):** 1-9.

Suresh, P., Johnson Rajeswar, J., Sukumar, K., Harikrishnan, T.J. and Srinivasan, P. (2020). Molecular analysis of oncogenicity associated gene "*vIL8*" of serotype 1 Marek's disease virus isolates from India. *Indian Journal of Animal Research.* **54(1):** 83-89. doi: 10.18805/ijar.B-3693.

Suvarna, K.S., Layton, C. and Bancroft, J.D. (2013). Bancroft's Theory and Practice of Histological Techniques (7th ed.). Churchill Livingstone, London.

Witter, R.L. and Schat K.A. (2003). Marek's disease. In Diseases of Poultry (11th ed., pp. 407-465). Iowa State University Press.

Witter, R.L., Calnek, B.W., Buscaglia, C., Gimeno, I.M. and Schat, K.A. (2005). Classification of Marek's disease viruses according to pathotype: Philosophy and methodology. *Avian Pathology*. **34(2):** 75-90.