



Long Bone Fractures in Cats and Dogs: Characteristics and Available Treatment in Algiers: A Retrospective Study of 66 Fractures

Rebouch Myriem^{1,4}, Bouabdallah Ryhan^{2,4}, Benmohand Chabha^{3,4},
Zenad Ouahiba^{3,4}, Hani Fatma Amira^{3,4}, Benfenatki Nacéra⁵

10.18805/ag.DF-688

ABSTRACT

Background: Fractures in domestic carnivores are frequently seen in veterinary medicine in the world and are mostly due to impacts inflicted by car injury, trauma, or falls. Fracture type and pattern influence treatment choice. No data are available on long bone fracture in Algiers to provide young veterinarians in developing countries with information on these fractures and their practical treatment options.

Methods: Cases of long bone fractures were identified from files of patients presented for surgical consultation at the Surgical Department of the Higher National Veterinary School of Algiers. Characteristics, such as age, sex, circumstances and fracture classification were analysed. The type of selected treatment was also noted, as was the follow-up, when possible.

Result: A total number of 66 fractures was recorded. Cats were more affected than dogs representing 70.7% versus 29.3% of the animals showing limb fractures (n=58). The proportions of males and females were respectively 65.9% and 34.1% in cats and 70.6% and 29.4% in dogs. Young animals under 12 months of age represented 82.9% of cats and 64.7% of dogs. Fall from a height was the primary cause in both cats and dogs (51.2% and 58.8%). Fracture of the femur was the most common fracture (51.1% in cats and 47.4% in dogs). Femoral fractures in cats were present on the proximal bone end in over 50 percent of cases. Among these, Eighty-three percent affected the head and/or neck of the bone. Most fractures were closed. Open fractures (23.4% in cats and 5.3% in dogs) affected the lower bones. Animals were treated by pinning, femoral head ostectomy, casting and, amputation (on open fractures of grade II and III). Assessing clinical outcome revealed that recovery in animals having undergone intramedullary pinning or cross pinning and femoral head ostectomy was estimate good in 96.43% of cases in cats and 77.78% in dogs.

Key words: Cats, Dogs, Fracture, Long bone, Pinning.

INTRODUCTION

Fractures in carnivores (cats and dogs) are commonly seen in veterinary practice. Fractures are well documented in Western countries. The hind limb is the most often affected. Beale (2004) found that femoral fractures reach 45% of all long bone fractures, followed by tibial ones. Young animals are more frequently affected than adults and males are likely to show fractures over females (Abo-Soliman *et al.*, 2020).

There are various ways to treat long bone fractures: Pins, plates, external fixators are the classical devices describes by DeCamp *et al.* (2016) and Aithal (2023). In some cases, however, conservative management is preferred for financial reasons and convenience. Pins are one of the simplest and most cost-effective osteosynthesis devices, which makes them an accessible tool for veterinarians in developing countries, where pet culture is not perceived as in western countries and where pet owners often lack the necessary financial means.

Only one study, conducted by Bouabdallah *et al.* (2020); describes fractures in Algeria, but concerned the Pelvis. Regarding the greater Maghreb, surveys on long bone fractures and their treatment in dogs and cats have been undertaken in Libya by Bennour *et al.* (2014) and especially

¹Research Laboratory HASAQ, Higher National Veterinary School Rabie Bouchama, El Alia, 16025, Algiers, Algeria.

²Research Laboratory GRAL, Higher National Veterinary School Rabie Bouchama, El Alia, 16025, Algiers, Algeria.

³Research Laboratory SPA, Higher National Veterinary School, El Alia Rabie Bouchama, 16025, Algiers.

⁴Higher National Veterinary School Rabie Bouchama, El Alia, Algiers, Algeria.

⁵Internal Medicine Department, Rouiba University Hospital Center, Rouiba, Algeria.

Corresponding Author: Rebouch Myriem, Research Laboratory HASAQ, Higher National Veterinary School Rabie Bouchama, El Alia, 16025, Algiers, Algeria. Email: m.rebouch@ensv.dz
Orcid: 0000-0003-4336-3197

How to cite this article: Myriem, R., Ryhan, B., Chabha, B., Ouahiba, Z., Amira, H.F. and Nacéra, B. (2024). Long Bone Fractures in Cats and Dogs: Characteristics and Available Treatment in Algiers: A Retrospective Study of 66 Fractures. *Agricultural Science Digest*. 1-7. doi: 10.18805/ag.DF-688.

Submitted: 15-10-2024 **Accepted:** 29-11-2024 **Online:** 08-01-2025

in Egypt by Ben Ali, (2013), Elzomor *et al.* (2014) and Abo Soleiman *et al.* (2020).

The aim of this study was to evaluate appendicular fractures in cats and dogs presented at the Surgery Unit of the Higher National Veterinary School of Algiers to describe their features, the type of applied treatment and outcome when possible and thus; to provide the Young Algerian veterinarians with information about long bone fractures in our pets and the possible successful available treatment options.

MATERIALS AND METHODS

The study, conducted from 2018 to 2023, analysed retrospectively; long bone fractures among 371 dogs and cats who underwent surgeries performed by the authors at the Surgery Department of the Higher National Veterinary School of Algiers. Data from animals presented for sterilization were excluded.

Characteristics were analysed, including age, sex, breed, lifestyle factors, as well as circumstances of injury. Affected limb, bone, location and type of fracture were reviewed. Concomitant injuries were recorded as well. All features were examined separately in cats and dogs.

Patients were treated by osteosynthesis (Stainless Pins and wires), femoral head ostectomy, conservative treatment and amputation. Surgical procedures were performed by two certified surgeons. When possible, follow-up at 2 months was recorded. Recovery was estimated as good (return to complete function), fair (normal function with slight limping) and poor (heavy lameness to impaired function).

Descriptive analysis was used to summarize the demographics and characteristics of the sample. Rates were calculated and analysed with Excel, 2010 version.

RESULTS AND DISCUSSION

Long bone fractures represented 16,9% of the total number of cats (n=41 of 243) and 13,28% of dogs (n=17 of 128) presented at the surgery Unit for examination. These results are slightly lower than in the world and even some North African surveys such as Bennour *et al.* (2014), who found very high rates of fractures in companion animals but meet those of Ben Ali (2013) who showed that fractures accounted for 17.8% of the total of presented cases. Cats were affected in 70,7% and dogs in 29,3% of all animals showing limb fractures (58 animals). A total number of 66 fractures was recorded. Some animals displayed more

than one fracture (n=6 cats and n=2 dogs). Ben Ali (2013) though, found that dogs were more prone to fractures than cats with dogs constituting 67% and cats 23% of the total in Egypt. Respective rates were 67.8% and 39.5% of the total surgical patients in Libya, for Bennour *et al.* (2014) which also are the opposite of our findings. It also differs from Libardoni *et al.* (2018), in which dogs were more represented. This could be linked to the fact that Algerian dog owners may avoid keeping dogs due to cultural considerations or preferring private practices over veterinary teaching hospitals, preventing students from handling their pets. The return to stability in Algeria may also explain the decreased need for watchdogs.

Our study showed male predominance in both cats and dogs (Table 1). Most available studies also registered higher rates for males: 57.45% for Cardoso *et al.* (2016), 61.50% for Shiju Simon *et al.* (2010) and 55.84% for Kushwaha *et al.* (2011). Keosengthong *et al.* (2019), however found that fractures in male dogs were predominant (58.4%) but similar proportions of males and females in cats (49.6% versus 50.4%). It is commonly admitted that males are more active and show more willingness to fight. The study's findings may also be attributed to general owners' preference for male companion animals to avoid unwanted pregnancies. Miranda *et al.* (2020) found that female bone maturity is reached earlier than that of males which may potentially contribute to higher fracture incidence in young males.

Young cats and dogs were more saffected than adults (Table 1). These results corroborate the studies of Cardoso *et al.* (2016); Shiju Simon *et al.* (2010); Vidane *et al.* (2014) and Minar *et al.* (2013): Young animals are more prone to fractures due to bone fragility associated with the growth plate and incomplete mineralization. Their playful and curious behaviour, imperfect motor coordination and immature soft tissues also increase their vulnerability to trauma.

Most cats were European Short Hair (73,2%) and Siamese (22%). Angora and Chartreux reached 2,4% each. This matches the observations of Libardoni *et al.* (2018) and of Cardoso *et al.* (2016), where cats were mostly undefined breeds. In Dogs, German Shepherds represented 29,4%, followed by Malinois (17, 3%), then Belgian Sheperd and Pitt Bulls (11,8%, each). Other breeds represented 5,9%, each. Unlike Shiju Simon *et al.* (2010), in our study,

Table 1: Sex and age and circumstances in dogs and cats.

Species	Sex			Age			Circumstances			
	Female	Male	Total	Young (<12 months)	Adults (>12 months)	Total	Unknown	Fall from a height	Car injury	Trauma
Cats	14 34.15%	27 65.85%	41 100.00%	34 85.00%	6 15.00%	40 100.00%	1	21 51.2%	14 34.1%	5 12.2%
Dogs	5 29.41%	12 70.59%	17 100.00%	11 64.71%	6 35.29%	17 100.00%		10 58.8%	3 17.6%	4 23.4%

Purebred large animals were predominant. This could be an illustration of the fact that dogs, in Algeria; are mainly bred as watchdogs, needing to impress. Also, young large dogs may be more susceptible to fractures from trauma because of the extra weight exerted on their bones, temporarily fragile due to their rapid growth. Their predisposition to some bone diseases also increases the risk.

We found that nineteen cats and seven dogs were kept indoor. Three indoor dogs were kept in “garages” and three others on “rooftops.” Cardoso *et al.* (2016) reported that most fractured cats were indoor pets. Fall from a height was the major cause in both cats and dogs (Table 1). This contradicts Keosengthong *et al.* (2019); Libardoni *et al.* (2016); and Miranda *et al.* (2020) who found that road accidents were the most frequent aetiology, but corresponds to Ben Ali (2013); Bennour *et al.* (2014); Kushwaha *et al.* (2011) and, Kumar *et al.* (2022) findings: where a fall accounted for 33,37% to 43,25% of causes. The low rates of road traffic accidents in our dogs may be due to their watchdog status and rooftop confinement, making them more susceptible to falls.

Eight cats (19.5%) suffered additional trauma: one spinal fracture, five pelvic fractures and diaphragmatic hernias accounted for 25% of these injuries. According to Griffon *et al.* (1994), 38.7% of fractured cats exhibit thoracic injuries, with a higher rate for more cranial fractures. Diaphragmatic hernias were observed in our study, but not at a very high rate. This could reflect the fact that most fractures involved the hindlimb.

Fracture description and classification

We report 36 cats affected with single fractures and five with multiple fractures, representing 87.8% and 12.2% of animals, respectively. Simple fractures reached 88,2% in dogs (n=15) and two dogs suffered multiple fractures (11,8%). All animals suffering from multiple fractures

displayed 2 fractures, except one cat, who had 3 fractures. Keosengthong *et al.* (2019) found higher rates (44.1% of dogs and 37.8% of cats) in Thailand. The reason may be that in the latter, road traffic accidents are the main cause of fracture, which is not the case in our study.

Rear limb fractures were the most common in both our cats and dogs, accounting for 80.9% and 63.2%, respectively. Minar *et al.* (2013) evaluated pelvic limb fractures at 37%, while Elzomor *et al.* (2014) reported 69.39% in cats and 50.60% in dogs. Harasen (2003) suggested that front limb fractures might be more fatal due to their proximity to vital organs, such as the head and thorax, which may not be captured in survey studies. Alternatively, we propose that animals trying to escape trauma may leave their rear limbs more vulnerable.

The distribution of long bone fracture is summarised in Fig 1. The femur was most affected in both cats and dogs. Tibial fractures were ranked second in cats and third in dogs. Elzomor *et al.*, (2014), Cardoso *et al.* (2016) and Libardoni *et al.* (2016) have stated that the femur and tibia were the most involved long bones. Our study revealed that dogs’ radius/ulna and humerus were affected in second and fourth place, only partially aligning with previous research findings: respectively reaching 17,6% and 7,5% for Vidane *et al.* (2014) in Brazil and 12,01% and 6,91% for Libardoni *et al.* (2016) in Mozambique, but matching Vani *et al.* (2022) who found that in dogs, radius/ulna was the second more frequently affected bone. Most of the body weight being applied on the forelimb in animal and large heavy dogs being overrepresented in our study may explain this higher rate. Metacarpal, metatarsal and, phalanx fractures where rare, which matches the results of Bennour *et al.* (2014) and Ben Ali (2013).

Table 2 summarizes fracture locations in dogs and cats. In cats, femoral head and neck fractures were highly represented, similar to findings of Cardoso *et al.* (2016) where they reached 42.86%. In dogs, contrary to Minar

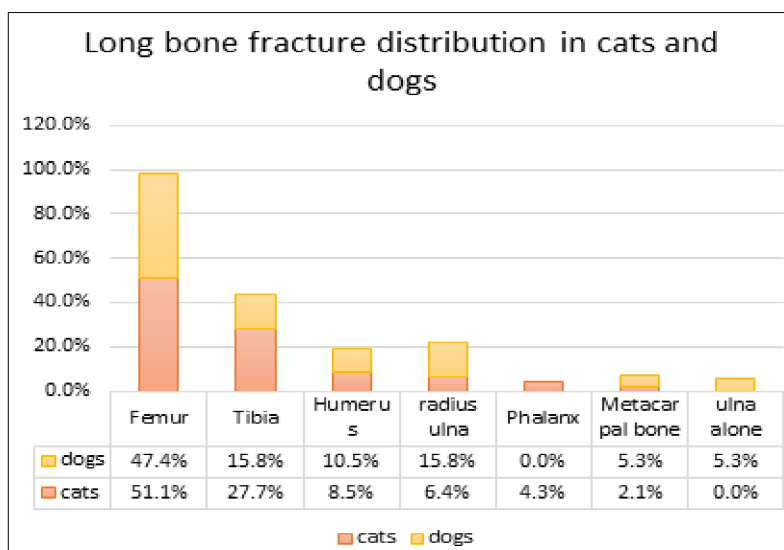


Fig 1: Bone fracture distribution in cats and dogs.

et al. (2013) and Libardoni *et al.* (2018), both proximal and distal fractures were equally common. Unlike in most studies, the major cause for fracture in both cats and dogs was a fall from a height: The vertical overloading force on limbs at the reception could explain the high rate of this fracture pattern (head and/r neck fractures) in our study, as proposed by Matis and Waibl (1985). Anggoro *et al.* (2024) finds that miniature dogs are more susceptible to distal fractures compared to larger dogs (our population), potentially explaining the difference with our results: We observed that most physeal fractures were noted on the femur, as did Rubinos and Meeson (2022). In our cats, diaphyseal tibial fractures were predominant. Abo Soleiman *et al.*'s (2020) findings align with this. Shiju Simon *et al.* (2010) declares that avulsion fractures in dogs were common in the tibia. We found that they were as represented as diaphyseal and distal ones. Gall *et al.* (2022) found that humeral and, Cardoso *et al.* (2016) that radial fractures were mainly diaphyseal, which matches our observations. Single ulnar fractures are rare according to Makar *et al.* (2024). Our results are consistent with that.

Comminuted fractures represented 12.2% to 17.8% for Keosengthong *et al.* (2019) and, 8.1% to 18.6% for Abo-Soliman *et al.* (2020) We found similar results (Table 3). Open fractures in our study were predominantly found in the tibia and paw bones (Table 3). Cardoso *et al.* (2016) found that open fractures reached (11.12%), the tibia being involved in 70% of cases. Low amounts of surrounding tissue in these bones are likely to be the cause.

Treatment and outcome

Fractures were treated from day 0 up to 52 days, (median time 7 days), due to late case presentation. Kushwaha *et al.* (2011) experienced the same issue in India. Table 4 lists the different types of treatment used. Pins were mostly

used. Intramedullary pins associated with cerclages are a suitable option when applied per the indications (Aithal *et al.* 2023; Sodhi *et al.* 2021). Multiple other devices are commonly used nowadays, such as plates, plates and rods, external fixators (Gall *et al.* 2022), but pinning is still considered an acceptable option to treat fractures (Kushwaha *et al.*, 2011; Priyanka *et al.*, 2019; Kumar *et al.*, 2023).

Femoral osteotomy may be used in chronic head/Neck fractures (Beale, 2004; Aithal *et al.*, 2023), which was the case in our study. In open fractures, Intramedullary pinning was only applied when complete immobilization could be achieved, as recommended by Glyde and Arnett (2006). External fixators are more indicated when available, as stated by Aithal *et al.*, (2023) and Singh *et al.* (2023), which was not the case in our study. Eccles *et al.* (2020) declares that amputating a leg may be beneficial for cats with significant soft tissue or neurovascular damage and when early treatment cannot be achieved. Beale (2004) and Aithal *et al.* (2023) consider cross pins -which were used in our study- as a good choice for Salter-Harris fractures.

Casts were applied on minimally displaced fractures. External coaptation can be considered for minimally displaced radial fractures when plating or external fixation is unavailable or refused by the owner (Palmer and Goh, 2020).

The study evaluated outcomes of 28 cats and nine dogs after osteosynthesis surgery. Cats had good outcomes (96.43%). One poor result was noted in a distal humerus (cross pins and an intercondylar pin). Optimal immobilisation of separated condyles is best achieved through a lag screw an Kirshner wires as shown by Beale (2004). In dogs, we registered good outcomes (77.78%), fairness (11.11%) and poor outcome (11.11%) for one intramedullary nail placement in the humerus. It is worth noting that we registered no non-unions.

Table 2 : Fracture localisation on bone.

Fracture in dogs	Femur	Rate	Humerus	Rate	Meta-carpus	Rate	Radius-Ulna	Rate	Tibia	Rate	Phalanx	Rate	Total	Rate
Distal	2	22.2%	1	50.0%		0.0%		0.0%	1	33.3%			4	21.1%
diaphyseal	5	55.6%	1	50.0%	1	100.0%	3	75.0%	1	33.3%			11	57.9%
Proximal	2	22.2%		0.0%		0.0%	1	25.0%	1	33.3%			3	15.8%
Total	9	100.0%	2	100.0%	1	100.0%	4	100.0%	3	100.0%	0		19	100.0%

Fracture in cats	Femur	Rate	Humerus	Rate	Meta-carpus	Rate	Radius-Ulna	Rate	Tibia	Rate	Phalanx	Rate	Total	Rate
Distal	7	29.2%	2	50.0%		0.0%	1	33.3%	4	30.8%		0.0%	14	29.8%
Diaphyseal	5	20.8%	2	50.0%	1	100.0%	2	66.7%	8	61.5%	1	50.0%	19	40.4%
Proximal	12	50.0%		0.0%		0.0%		0.0%	1	7.7%	1	50.0%	14	29.8%
Total	24	100.0%	4	100.0%	1	100.0%	3	100.0%	13	100.0%	2	100.0%	47	100.0%

Table 3: fracture type in cats and dogs.

Fracture type	Closed	Open	Comminuted	Simple	Total
In cats	36	11	8	39	47
Rate	76.60%	23.40%	17.25%	82.75%	100.00%
In dogs	18	1	4	15	19
Rate	94.74%	5.26%	18.18%	81.82%	100.00%

Table 4: Treatment performed in cats and dogs.

Treatment	Femur		Tibia		Humerus		Radius/ulna		Metacarpus		Phalanx		Fracture
	Cat	Dog	Cat	Dog	Cat	Dog	Cat	Dog	Cat	Dog	Cat	Dog	
Cross Pins	2	1	1										Distal, proximal, Salter-Harris
Cross pins + tension band wire			1										Proximal Salter-Harris and tibial crest
Intramedullary Pin	7	3	5		2	1	1						Diaphyseal transverse
Intramedullary Pin and cerclage	2	2			1	1							Diaphyseal comminute and oblique
Cross Pins + intercondylar Pin					1								Distal and Intercondylar fracture
Tension Band Wire		1		1									Trochanteric, tibial crest
Femoral Head Ostectomy	8	1											Head/Neck fracture
Excision								1					Anconeal process fracture
Amputation			6	1								1	Open type 2 and 3 fracture
Cast								1	3	1	1		Non displaced, stable
No surgery	5	1		1				1				1	Spontaneous recovery or not attending appointment
Total	47 in cats						19 in dogs						

CONCLUSION

Fractures in cats and dogs are commonly seen in Algiers. Young males under 12 months of age are mainly affected. Fall from a height is the main identified cause. The femur is the most frequently involved bone. Proximal femur fracture (head and/or neck) are highly represented. Simple closed fractures are more often observed than open or comminuted ones.

In emergent countries, Veterinarians must often deal with available means and owners' willingness to treat their pets at a lower cost, but we can conclude that results obtained using intramedullary or cross pins are globally satisfying when treatment choice is made in accordance with recommendations. Femoral head and/or neck fracture reached high rates in our study and were treated by Femoral Head Ostectomy, resulting in very good outcomes.

ACKNOWLEDGEMENT

This study was supported by internal fundings from the Department of Surgery of the Higher National Veterinary

School of Algiers, Algeria, in the context of management of patients presented for surgical treatment. The authors would like to thank M. Bouhous R. and Dr Tiouririne A. for their assistance.

Disclaimers

The views and conclusions expressed in this article are solely those of the authors and do not necessarily represent the views of their affiliated institutions. The authors are responsible for the accuracy and completeness of the information provided, but do not accept any liability for any direct or indirect losses resulting from the use of this content.

Informed consent

The investigations protocol was based on the clinical examination and treatment of animals seen at the Department of Surgery of the Higher National Veterinary School of Algiers, Algeria. No experimental procedure was performed. The treatments applied were based on techniques validated and standardised in veterinary orthopaedics.

Conflict of interest

The authors declare that there are no conflicts of interest regarding the publication of this article. No funding or sponsorship influenced the design of the study, data collection, analysis, decision to publish, or preparation of the manuscript.

REFERENCES

- Abo-Soliman, A.A.M., Ahmed, A.E. and Farghali, H.A. (2020). Incidence of appendicular bone fracture in dogs and cats: Retrospective study at veterinary hospital of cairo university and some private clinics in egypt. *World's Veterinary Journal*. 10(4): 638-652. <https://dx.doi.org/10.36380/scil.2020.wvj>.
- Aithal, H.P., Pal, A., Kinjavdekar, P. and Pawde A.M. (2023). Textbook of Veterinary Orthopaedic Surgery. 1st ed. Springer Singapore. XVIII, 459. <https://doi.org/10.1007/978-981-99-2575-9>.
- Anggoro, D., Purba, M.S., Jiang, F., Nishida, N., Itoh, H., Itamoto, K., Neomoto, Y., Nakaichi, M., Sunahara, H. and Tani, K. (2024). Elucidation of the radius and ulna fracture mechanisms in toy poodle dogs using finite element analysis. *Journal of Veterinary Medical Science*. 86(5): 575-583. 2024. <https://doi:10.1292/jvms.23-0520>.
- Beale, B. (2004). Orthopaedic clinical techniques: Femur fracture repair. *Clinical Techniques in Small Animal Practice*. 19 (3): 134-150. <https://doi.org/10.1053/j.ctsap.2004.09.006>.
- Ben Ali, L.M., (2013). Incidence, Occurrence, Classification and Outcome of Small Animal Fractures: A Retrospective Study (2005-2010). *International Journal of Animal and Veterinary Sciences*. 75: 628-633. <https://doi.org/10.5281/zenodo.1082359>.
- Bennour, E.M., Abushhiwa, M.A., Ben Ali, L., Sawesi, O.K., Marzok, M.A., Abuargob, O.M., Tmumen, S.K., Abdelhadi, J.A., Abushima, M.M., Benothman, M.E., Said, E.M. and El-Khodery, S.A. (2014). A Retrospective Study on Appendicular Fractures in Dogs and Cats in Tripoli - Libya. *Journal of Advanced Veterinary and Animal Research*. 4(3) : 425-431.
- Bouabdallah, R., Meghrief, F.Z., Azzag, N., Benmohand, C., Zenad, W. and Rebouh M. (2020). Conservative management of pelvic fractures in dogs and cats in Algiers: Incidence and long-term clinical outcomes. *Veterinary World*. 13 (11): 2416-2421. www.doi.org/10.14202/vetworld.2020.2416-2421.
- Cardoso, C.B., Canevese, R.S., Agostinho, F.S., Mamprim, M.J., Santos, R.R., Filho, E.S., Mortari, A.C. and Monteiro, F.O.B. (2016). Long bone fractures in cats: a retrospective study. *Veterinária e Zootecnia*. 23(3): 504-509.
- DeCamp, C.E., Johnston, S.A., Déjardin, L.M. and Schaefer, S.L. (2016). Fractures: classification, diagnosis and treatment. In: Brinker, Piermattei and Flo's Handbook of Small Animal Orthopaedics and Fracture Repair, 5e, 139-144. (St Louis, MO, Elsevier), 24-152. <https://doi.org/10.1016/B978-1-4377-2364-9.00011-2>.
- Eccles, S., Handley, B., Khan, U., McFadyen., Nanchahal, J., Naya-gam, S., (2020). editor(s). Standards for the management of open fractures. Oxford, 2020; online edn, Oxford Academic, 1 Aug. 2020. (accessed July 2024). <https://doi.org/10.1093/med/9780198849360.001.0001>.
- Elzomor, S.T., Sheta, E.M.E., Farghali, H.A. and Ashour, A.E. (2014). Prevalence of femoral fractures in dogs and cats. *Journal of the Egyptian Veterinary Medical Association*. 74 (2): 269 - 278.
- Gall, N., Parsons, K., Radke, H., Comerford, E., Mielke, B., Grierson, J., Ryan, J., Addison, E., Logethelou, V., Blaszyk, A. and Langley-Hobbs, S.J. (2022). Analysis of feline humeral fracture morphology and a comparison of fracture repair stabilisation methods: 101 cases (2009-2020). *Journal of Feline Medicine and Surgery*. 24(6), e19-e27. <https://doi.org/10.1177/1098612X221080600>.
- Glyde, M. and Arnett, R. (2006). Tibial fractures in the dog and cat: Options for management. *Irish Veterinary Journal*. 59(5): 290-295.
- Griffon, D.J., Walter, P.A. and Wallace, L.J. (1994). Thoracic Injuries in Cats with Traumatic Fractures. *Veterinary and Comparative Orthopaedics and Traumatology*. 7, 98-100. <https://doi.org/10.1055/s-0038-1633128>.
- Harasen, G. (2003). Common long bone fractures in small animal practice- part 1. *The Canadian Veterinary Journal*. 44(4): 333.
- Keosengthong, A., Kampa, N., Jitpean, S., Seesupa, S., Kunkitti, P. and Hoisang, S. (2019). Incidence and classification of bone fracture in dogs and cats: A retrospective study at a Veterinary Teaching Hospital, Khon Kaen University, Thailand (2013-2016). *Veterinary Integrative Sciences*. 17(2): 127-139.
- Kumar, P.R., Prasad, V.D., Sreenu, M., Naidu, G.V. and Raju, N.K.B. (2022). Incidence, Occurrence and Classification of Long Bone Fractures in Dogs: A Retrospective Study. *Indian Journal of Animal Research*. B-4876: 1-5. <https://doi.org/10.18805/IJAR.B-4876>.
- Kumar, A.R.N., Chaudhary, R.N., Ram R. and Priyanka (2023). Titanium Elastic Stable Intramedullary Nailing for the Repair of Long Bone Fractures in Dogs. *Indian Journal of Animal Research*. 19(3): 26-29. <https://doi.org/10.48165/ijvsbt.19.3.06>.
- Kushwaha, R.B., Gupta, A.K., Bhadwal, M.S., Kumar, S. and Tripathi, A.K. (2011). Incidence of fractures and their management in animals: A clinical study of 77 cases. *Indian Journal of Veterinary Surgery*. 32(1): 54-56.
- Libardoni, R.D., Da Costa, D., Menezes, F.B., Cavalli, L.G., Pedrotti, L.F., Kohlrausch, P.R., Minto, B.W. and Silva, M.A.M. (2018). Classification, fixation techniques, complications and outcomes of femur fractures in dogs and cats: 61 cases (2015-2016). *Ciência Rural*. 48 (06). <http://dx.doi.org/10.1590/0103-8478cr20170028>.
- Libardoni, R.N., Serafini, G.M.C., Oliveira, C., Schimite, P.I., Chaves, R.O., Feranti, J.P.S., Costa, C.A.S., Amaral, A.S., Raiser, A.G. and Soares, A. (2016). Appendicular fractures of traumatic etiology in dogs 955 cases (2004-2013). *ciência Rural*. 46(3): 542-546. <http://dx.doi.org/10.1590/0103-8478cr20150219>.
- Makar, J.G., Lai, J.Y., Simcock, J.O., Jerram, R. M., Lai, A., Levien, A.S., Hoon, Q.J., Hall, E.J. and Basa, R.M. (2024). Feline radial and ulnar diaphyseal fractures: A retrospective study of 49 cases comparing single bone fixation and dual bone fixation. *Journal of Feline Medicine and Surgery*. 26(2): 1-13. <https://doi.org/10.1177/1098612X231214930>.
- Matis, U. and Waibl, H. (1985). Proximal femoral fractures in cats and dogs. *Tierärztliche Praxis*. Supplement.1: 159-178.
- Minar, M., Hwang, Y., Park, M. Somin, K., Cheongjin, O., Seokhwa, C. and Gonhyung, K. (2013). Retrospective study on fractures in dogs. *Journal of Biomedical Research and Environmental Sciences*. 3(14): 140-144. <https://doi.org/10.12729/jbr.2013.14.3.140>.

- Miranda, F.G., Souza, I.P., Viegas, F.M., Megda, T., Nepomuceno, A.C., Tôrres, R.C. and Rezende, C.M. (2020). Radiographic study of the development of the pelvis and hip and the femorotibial joints in domestic cats. *Journal of Feline Medicine and Surgery*. 22(6): 476-483. <https://doi.org/10.1177/1098612X19854809>.
- Palmer, R. and Goh, C.S.S. (2020). Definitive Treatment of Limb Fractures with Splints or Casts. *today's veterinary practice*. com: 43-56. accessed on July 2024.
- Priyanka T.S., Mohindroo, J., Pallavi, V., Udheiya, R. and Umeshwori, N. (2019). Evaluation of intramedullary pinning technique for management of tibia fractures in dogs. *The Pharma Innovation Journal*. 8(2): 291-297.
- Rubinos, C. and Meeson, R. L. (2022). Traumatic physeal fractures in cats: A review of 36 cases (2010-2020). *Journal of Feline Medicine and Surgery*. 24(2): 98-106. <https://doi.org/10.1177/1098612X211005886>.
- Shiju Simon, M., Ganesh, R., Ayyappan, S., Rao, G.D., Kumar, S.R., Kundave, V.R. and Das, B.C. (2010). Incidences of pelvic limb fractures in dogs: A survey of 478 cases. *Veterinary World*. 3(3): 120-121.
- Singh, T., Kumar, A., Udehiya, K.R., Gill, K. K., Rai, S.T. and Mahajan, K.S. (2023). Outcome of Open Long Bone Fractures in Dogs Stabilized with Linear External Skeletal Fixator. *Indian Journal of Animal Research*. 57(1): 120-125. <https://doi.org/10.18805/IJAR.B-4262>.
- Sodhi, S.H., Kumar, A., Anand, A., Sangwan V. and Singh O. (2021). Comparison of titanium elastic nailing and end-threaded intramedullary pinning for distal femoral fractures in young dogs. *Indian Journal of Animal Research*. 57(9): 1186-1193. <https://doi.org/10.18805/IJAR.B-4454>.
- Vani, G., Veena, P. and Kumar R.V.S. (2022). Incidence of Long Bone Fractures in Canine. *Indian Journal Of Canine Practice*. 14(1): 28-29. <https://doi.org/10.29005/IJCP.2022.14.1.28-29>.
- Vidane, A.S., Elias, M.Z.J., Cardoso, J.M.M., Come, J.A.S.S., Harun, M. and Ambrosio, C.E. (2014). Incidência de fraturas em cães e gatos da cidade de Maputo (Moçambique) no período de 1998-2008. *Ciencia Animal Brasileira*. 15 (4): 490-494. <https://doi.org/10.590/1089-6891v15i424279>.